


Aphthous-like stomatitis of COVID-19 patients: case report and review of evidence

Nuraldeen Maher Al-Khanati^{1,2,*} , Abanoub Riad³,
Mhd Eyad Sahloul², Miloslav Klugar³

¹ Department of Oral and Maxillofacial Surgery, Faculty of Dentistry, Syrian Private University, Damascus, Syria

² Department of Oral and Maxillofacial Surgery, Faculty of Dental Medicine, Damascus University, Damascus, Syria

³ Czech National Centre for Evidence-Based Healthcare and Knowledge Translation (Cochrane Czech Republic, Czech EBHC: JBI Center of Excellence, Masaryk University GRADE Centre), Institute of Biostatistics and Analyses, Faculty of Medicine, Masaryk University, Brno, Czech Republic

Corresponding author:

Dr. Nuraldeen Maher Al-Khanati,
Department of Oral and Maxillofacial Surgery, Faculty of Dentistry, Syrian Private University, P.O. Box 36822, Damascus, Syria.
Email: nuraldeen.alkhanati@gmail.com, Phone: +963 956589272, ORCID: 0000-0001-9069-5069

Received: September 23, 2020

Accepted: September 24, 2020

Keywords: Stomatitis, aphthous. Coinfection. Coronavirus Infections. Oral manifestations.

Dear Editor,

The emerging evidence on oral symptoms that occur in conjunction with coronavirus disease (COVID-19) infection has triggered wide debates on the pathophysiology as well as the potential implications of these manifestations¹. Hereby, we aim to report according to the CARE guidelines the clinical characteristics of a COVID-19 patient with aphthous-like stomatitis from our clinic². We also performed a literature search in PubMed, Scopus, Google Scholar from inception until 6th of September 2020 with a combination of keywords (COVID-19 OR SARS-CoV-2) AND aphthous.

A 24-year-old male patient sought care at our clinic (Damascus, Syria) due to a burning sensation and pain related to his lower lip. The medical history of the patient revealed no underlying systemic comorbidity but sub-clinical hyperthyroidism, and the patient was a non-smoker. Among his household, two members were laboratory-confirmed COVID-19 cases; therefore, the patient was instructed to do self-isolation at home for two weeks. Immediately after starting the quarantine, the patient presented mild symptoms



such as headache and on the same day, he reported two aphthous-like ulcers that started developing on the mucosa of the lower lip. The patient also complained of a burning sensation in the tongue. On the following day, the severity of the symptoms started to get worse. The patient complained of very severe pain all over the body, especially the area of the shoulders, lower back, and knees joints. General fatigue was accompanied by very severe headache, dizziness, loss of appetite, and nausea with a high temperature that reached slightly more than 38 degrees that night.

On the third day, joints pain increased dramatically with a further rise in body temperature which reached 40.5 degrees at night, and an increase in the size of aphthous-like stomatitis 1.5-1.7 cm. These ulcers on the labial mucosa became so painful that the chewing and speech functions were greatly impaired. To make the situation worse, the patient complained of severe pain in the throat, increased burning sensation from the tongue, and oral halitosis. On intraoral examination, inflammatory and purulent areas were found in the pharyngeal wall. The tongue was affected variedly by areas of overgrowth and absence of filiform papillae. It was noteworthy that the burning sensation in the tongue was manifested mainly in the morning and noon, while it regressed a lot at night (Figure 1).

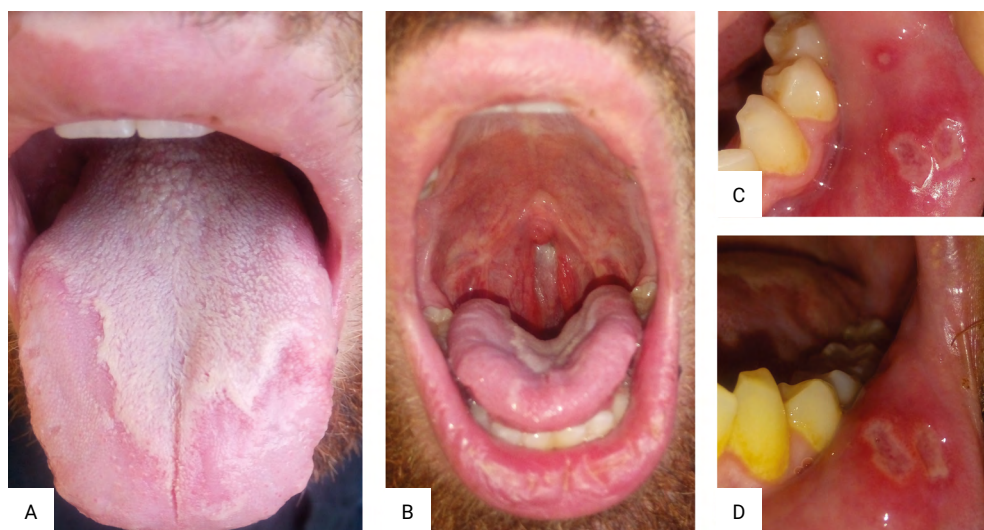


Figure 1. Oral manifestations of the reported case; a: depapillated areas from the anterior and lateral parts of the tongue associated with burning sensation. b: erythema and purulent exudate from the posterior pharyngeal wall. c: after three days of onset of aphthous-like stomatitis. d: after four days of onset of aphthous-like stomatitis erythematous irregular margins on the labial mucosa.

Although the patient was treated with analgesic and antipyretic drugs, the body temperature did not drop below 38.5 degrees, and this continued on the fourth and fifth days from the onset of symptoms of infection. Case management included an intravenous infusion of nutrient solutions and antipyretic and analgesic medication, i.e. acetaminophen. As the multiple painful aphthous-like stomatitis on the labial mucosa increased in size, the patient was instructed to apply honey as a topical treatment.

However, it was obvious that the patient was infected by COVID-19 based on clinical scenario and symptoms, the polymerase chain reaction (PCR) testing was not required nor performed due to the severely limited resources in Syria.

By referring to what the patient reported, all his family members who had been infected with COVID-19 had this trilogy of oral manifestations “aphthous-like lesions and depapillated areas on the tongue with a burning sensation”. This might suggest a genetic predisposition to the occurrence of these oral signs and symptoms associated with COVID-19. The investigated patient agreed to use his clinical results for academic purposes while concealing his identifying personal data.

Many viruses, including cytomegalovirus, herpes simplex virus and Zika virus, are capable of infecting the oral mucosa and causing very painful oral ulcers. Few studies have described COVID-19-associated oral manifestations. On reviewing the emerging evidence of aphthous lesions in COVID-19, we have found that 14 cases were reported heretofore³⁻⁷ (Table 1). Nine patients (64.3%) were males, while the rest were females (35.7%). Their mean age was 43.79 ± 19.32 years old, and more than half of them came from Latin American countries while the rest were from southern Europe and the Middle East. Most of the cases had aphthous lesions on non-keratinized mucosa such as soft palate, labial and buccal mucosa. All patients reported pain associated with the aphthous lesions.

Table 1. COVID-19 patients with aphthous lesions

Study, Location	Number	Gender	Age	Laboratory*	Type	Description
Dominguez-Santas et al. 2020, Madrid (Spain)	4	1 Female; 3 Males	43; 33; 37; 19	Confirmed	Minor aphthous ulcers	All lesions measured less than 1 cm. They mainly affected the nonkeratinized mucosa. The majority of them had a creamy-colored fibrin surface with an erythematous peripheral ring.
Malih et al. 2020, Tehran (Iran)	1	Male	38	Confirmed	Aphthous lesion	Erythema and aphthous ulcer developed on left tonsil, which was found on laryngeal exam.
Corchuelo et al. 2020, Cali (Colombia)	1	Female	40	Confirmed	Aphthous lesion	Painful aphthous ulcerative lesion developed on the attached gingiva of the first lower premolar.
Brandão et al. 2020, Sao Paulo (Brazil)	7	2 Females; 5 Males	81; 83; 72; 32; 35; 29; 28	Confirmed	Aphthous-like stomatitis	Multiple shallow aphthous-like painful lesions of varying sizes covered with mucopurulent membrane found in the upper and lower labial mucosa and in the anterior dorsal tongue.
Rodríguez et al. 2020, Madrid (Spain)	1	Female	43	Confirmed	Aphthous-like stomatitis	In addition to the aphthous-like ulceration, the patient reported burning tongue sensation and tongue depapillation.

* Laboratory confirmation of the SARS-COV-2 infection by means of polymerase chain reaction (PCR) testing

To conclude, aphthous-like stomatitis as a characteristic condition of immuno-affected patients is a predictable and clinically relevant oral complication of COVID-19 patients. Further studies are warranted to establish its epidemiologic significance and to understand its pathophysiology in COVID-19 patients.

References

1. Riad A, Klugar M, Krsek M. COVID-19-Related Oral Manifestations: Early Disease Features? *Oral Dis.* 2020 Jun 30;10.1111/odi.13516. doi: 10.1111/odi.13516.
2. Gagnier JJ, Kienle G, Altman DG, Moher D, Sox H, Riley D, et al. The CARE Guidelines: Consensus-based Clinical Case Reporting Guideline Development. *Glob Adv Health Med.* 2013 Sep;2(5):38-43. doi: 10.7453/gahmj.2013.008.
3. Díaz Rodríguez M, Jimenez Romera A, Villarroel M. Oral manifestations associated to Covid-19. *Oral Dis.* 2020 Jul 22;10.1111/odi.13555. doi: 10.1111/odi.13555.
4. Brandão TB, Gueiros LA, Melo TS, Prado-Ribeiro AC, Nesrallah ACFA, Prado GVB, et al. Oral lesions in patients with SARS-CoV-2 infection: could the oral cavity be a target organ? *Oral Surg Oral Med Oral Pathol Oral Radiol.* 2020 Aug 18;S2212-4403(20)31119-6. doi: 10.1016/j.oooo.2020.07.014.
5. Corchuelo J, Ulloa FC. Oral manifestations in a patient with a history of asymptomatic COVID-19: Case report. *Int J Infect Dis.* 2020 Sep 1;100:154-7. doi: 10.1016/j.ijid.2020.08.071.
6. Dominguez-Santas M, Diaz-Guimaraens B, Fernandez-Nieto D, Jimenez-Cauhe J, Ortega-Quijano D, Suarez-Valle A. Minor aphthae associated with SARS-CoV-2 infection. *Int J Dermatol.* 2020 Aug;59(8):1022-3. doi: 10.1111/ijd.15004.
7. Malih N, Hajinasrollah G, Zare M, Taheri M. Unexpected Presentation of COVID-19 in a 38-Year-Old Male Patient: A Case Report. *Case Rep Dermatol.* 2020 Jul 29;12(2):124-31. doi: 10.1159/000509994.