





Histopathological evaluation of the effect of *Salvadora persica* and *Nigella sativa* on the healing of tooth extraction socket in animal

Ali Idrees Al-Niaimi¹ , Noor A. Sulaiman^{1*} , Huda A. Salim¹ , Faris Ghanim Ahmed Al-Tae² 

¹ Department of Oral and Maxillofacial Surgery, College of Dentistry, Mosul University, Iraq.

² Department of Dental Basic Sciences, College of Dentistry, Mosul University, Iraq.

Corresponding author:

Noor A. Sulaiman
Address: Al- Muthanna street,
Mosul, Iraq.
e-mail: noorabdullah@uomosul.edu.iq
telephone number: 009647704818554

Editor: Altair A. Del Bel Cury

Received: Mar 12, 2022

Accepted: Oct 10, 2022



Aim: to assess the effects of *Salvadora persica* and *Nigella sativa* combination in tooth socket healing after extraction that can be a novel remedy for tooth extraction socket.

Methods: Forty rabbits were included in this study, divided into two groups (control and experimental) with 20 rabbits. Upper right central incisors were extracted for all animals, the tooth sockets of the experimental group were dressed using an admix of *Salvadora persica* and *Nigella sativa* immediately after irrigation with normal saline. In contrast, the extraction sockets of the control group were left without dressing. Biopsies were taken after euthanizing the animals at 1, 3, 7, and 14 days after treatment, histological examination was done for the samples at the given periods respectively. **Results:** On day 1 post-treatment, histological examination of the experimental group sections showed less acute inflammatory reaction than the control group. This continued to be reduced until the seventh day. The amount of granulation tissue formation was more in the experimental group along the different periods of the study, while new bone formation was observed after 1 week as woven bone, increased after 2 weeks and appeared as woven and lamellar bone in both experimental and control groups. **Conclusions:** A mixture of *Salvadora persica* and *Nigella sativa* has an anti-inflammatory effect and accelerate bone healing by stimulating bone formation in the tooth extraction socket.

Keywords: Tooth extraction. Tooth socket. Wound healing. Animals.

Introduction

Dental extraction is a commonly performed dental procedure that may be needed due to unrestorable tooth decay, periodontal disease, or dental trauma, also in orthodontics, sound teeth may be extracted to create a space to aid in teeth alignment¹. Healing of the socket is a multifaceted process, comprising proper cell attraction into the wound, differentiation of mesenchymal cells to bone-forming cells, proliferation of these cells, extracellular matrix production, mineralization, maturation, bone remodeling¹.

Bone resorption is among the consequences of dental extraction that can affect alveolar bone ridge dimension, and can make dental implant treatment difficult, it also impairs the long-term functional stability of the implant and esthetic results of prosthodontics treatment. Thus, the socket preservation concept was introduced to reduce bone loss and preserve the dental alveolus (tooth socket). so the dental implant can be performed immediately after tooth extraction, and better orofacial dimension can be retained in cases of alveolar ridge maintenance rather than in cases without ridge preservation^{2,3}. Several biomaterials have been reported for socket augmentation, including bone grafts, platelet-rich plasma, platelet-rich fibrin, bone morphogenetic protein, emdogain, and cell therapy⁴. International attention on herbal therapies for different disorders has greatly increased owing to their optimistic results and unusual reverse side effects. World Health Organization (WHO) reported that most of the general population, especially in developing regions, depend on natural remedies and old-fashioned herbal therapies for various conditions thus, to improve the success of health care systems. The WHO has encouraged the use of these therapeutic herbs⁵.

Among these herbs are *Salvadora persica* (SP) and *Nigella sativa*(NS). *S. persica*, commonly known as the miswak tree, belongs to the family Salvadoraceae and is present in extensive geographic distribution from Rajasthan (India), Nepal, Malaysia, Pakistan, Iran, Arabian island, North, and West South Africa⁶. It contains a wide range of organic and inorganic components and is used as an anticariogenic agent in several countries as it is easy to use and inexpensive. Moreover, it comprises ~1.0 µg/g of total fluoride and it releases calcium and phosphorus into water⁷. *S. persica* has many pharmacological activities, such as antibacterial, antifungal, antiplaque, hypolipidemic, antiulcer, anticonvulsant, anti-inflammatory, antifertility, and antioxidant⁶. These properties are related to its contents, including potassium and sodium chloride, salvadorine, vitamin C, salvadorene, silica, saponins, and various minerals⁵.

N. sativa is also known as black cumin or habatus sauda. This black seed is a herbal plant of the Ranunculaceae family, which chemically comprises volatile and non-volatile oils and various active elements, such as proteins, alkaloids, coumarins, saponins, minerals, carbohydrates, phenolic compounds, and steroidal complexes⁸. *N. sativa* has the highest concentration of thymoquinone (TQ) at [30% - 48%]; this element acts as an effective antioxidant, and encourages osteoblast differentiation concurrently with bone morphogenetic protein-2 (BMP-2), thus it is used in osteoporosis cases and bone healing^{9,10}. It also has other therapeutic properties such as

antidiabetic, antioxidant, anticonvulsant, anticancer, regulate immunity, analgesic, antimicrobial, anti-inflammatory, relaxative, bronchial dilation, and gastric tract, liver and kidney protection⁹.

In this study, we hypothesized that the application of a novel mixture of *S. persica* and *N. sativa* in dental sockets following tooth extraction has an anti-inflammatory action and accelerates the healing by increasing the bone formation rate.

Materials and Methods

The study protocol was approved by the scientific and ethical committee of Dentistry College in Mosul University (code no. UoM.Dent/A.L.48/21) given on June 15, 2021.

Medication

The dressing used in this study is a novel dressing created by the authors that consists of miswak (*S. persica*) and black seed (*N. sativa*) oil. *S. persica* was prepared by grinding the sticks in a sterile pack using a mortar and pestle; then, it was reground by using a sterile electrical grinder to obtain a more fine powder. The black seed oil (from a local market) (Emmad factory for oil production, Mosul, Iraq permit NO. 70490) was also sterile. The two compounds were admixed by a ratio of V/V to obtain dark brown grease granular mixture and then kept in a dark disinfected well-sealed container.




Figure 1. A: Miswak (*Salvadoria persica*). B: The black seed (*Nigella sativa*).

Animals

Forty mixed breed rabbits were used in this study (20 male and 20 female) weighing between 2.2 and 2.8 kg. The animals were divided into two groups control (n=20) and experimental (n=20). After anesthetizing the animals by intramuscular (in the rabbit thigh muscle) injection of a combination of 40 mg/kg ketamine and 4 mg/kg of xylazine^{11,12}, when required, supplementary sedation using these same medications was performed. Within 5 min, complete anesthesia had been achieved. Then local anesthesia (1 ml of 2% lidocaine with epinephrine 1:80,000, New Stetic com. Colombia) was administered. Subsequently, the upper right central incisors were

extracted from the animals by forceps after luxation by an elevator, the socket was then irrigated with normal saline. The tooth sockets of the experimental group rabbits were dressed using the admix of miswak and black seed oil immediately after irrigation with normal saline, whereas the extraction sockets of the control group were left without dressing. Five animals from each group were sacrificed after 1,3,7, and 14 days. The maxilla was removed and immersed in 10% formalin for 48 hours; the anterior part of the maxilla was dissected and then cut tangentially to the distal surfaces then decalcified in 5% formic acid for 1 month¹³. The samples were dehydrated in a graded alcohol series and embedded in paraffin wax. The blocks were sectioned by using microtome yielding sections of 5 µm thickness, the sections were stained with hematoxylin and eosin and analyzed using a light microscope. The following points were evaluated, acute inflammation reaction, granulation tissue (GT) formation, and bone formation.

The histological evaluation depended on the following scores according to Lucaciu et al.'s¹⁴ study with some modifications.

Acute inflammatory reaction	(0) No inflammation	(1) Mild	(2) Moderate	(3) Severe
Granulation tissue formation	(0) No granulation tissue	(1) Little	(2) Moderate	(3) Profound
Bone formation	(0) No bone formed	(1) Woven bone	(2) Woven and lamellar bone	(3) Lamellar bone

Data analysis

The data of the parameters appeared as mean rank with standard deviation (SD), IBM SPSS Statistics version 25.0 used for all data analyses. Man-Whitney U test was used for non-parametric data comparison between two groups. P-value ≤ 0.05 was considered significant.

Results

Animals were clinically healthy at the time of enutrition. All samples in the study evaluated by a histopathologist not show any infections, dehiscence, or defects. The histopathological results exposed the variances in the parameters means between the two groups. After 1 day, histological examination of the experimental group sections showed lesser acute inflammatory reaction with a mean rank (of 3.9) than that of the control group with a mean rank (of 7.0), which continued to be reduced until the seventh-day mean rank (4.0) in the experimental group. Moreover, the amount GT formation was greater in the experimental group along the different time periods, although new bone formation was observed after 1 week as woven bone with a mean rank (of 6.7) in almost all study samples. The control group had a mean rank (of 4.3), and the amount of new bone formation was increased after 2 weeks and appeared as a woven and lamellar bone in both experimental and control groups. The histopathological findings with differences between the two groups are presented in Tables 1, 2, and 3.

Table 1. Acute Inflammatory Reaction

Periods	Mean Rank \pm S.D. for control Group.	Mean Rank \pm S.D. for experimental Group.	Man-Whitney U test	P- Value
Day 1	7.100 \pm 0.678	3.900 \pm 0.535	4.500	0.077
Day 3	6.000 \pm 0.497	5.000 \pm 0.148	10.000	0.317
Day 7	7.000 \pm 1.141	4.000 \pm 0.540	5.000	0.050*
Day 14	5.500 \pm 0.000	5.500 \pm 0.000	12.500	1.000

All scores appear as Mean Rank \pm Standard deviation

* Significant at $P \leq 0.05$.

Table 2. Granulation Tissue Formation

Periods	Mean Rank \pm S.D. for control Group.	Mean Rank \pm S.D. for experimental Group.	Man-Whitney U test	P- Value
Day 1	6.000 \pm 0.295	5.000 \pm 0.089	10.000	0.317
Day 3	3.000 \pm 0.179	8.000 \pm 0.217	0.000	0.003*
Day 7	4.800 \pm 0.975	6.200 \pm 0.378	9.000	0.419
Day 14	5.900 \pm 0.570	5.100 \pm 0.447	0.606	1.000

All scores appear as Mean Rank \pm Standard deviation

* Significant at $P \leq 0.05$

Table 3. Newly Formed Bone

Periods	Mean Rank \pm S.D. for control Group.	Mean Rank \pm S.D. for experimental Group.	Man-Whitney U test	P- Value
Day 1	5.50 \pm 0.000	5.50 \pm 0.000	12.500	1.000
Day 3	5.00 \pm 0.000	6.00 \pm 0.447	10.000	0.317
Day 7	4.30 \pm 0.657	6.70 \pm 0.594	6.500	0.166
Day 14	5.00 \pm 0.570	6.00 \pm 0.626	10.000	0.549

All scores appear as Mean Rank \pm Standard deviation

* Significant at $P \leq 0.05$.

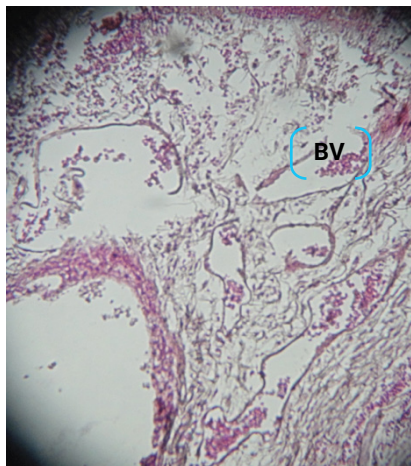


Figure 2. Biopsy of control group (day 1) Show acute inflammation with many dilated blood vessels (BV) and infiltration of acute inflammatory cells, mainly polymorphonuclear leukocytes.

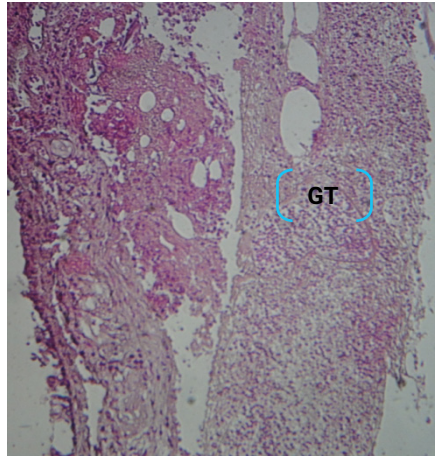


Figure 3. Biopsy of experimental group (day 1) show infiltration of acute inflammatory cells and little amount of granulation tissue (GT) formation.

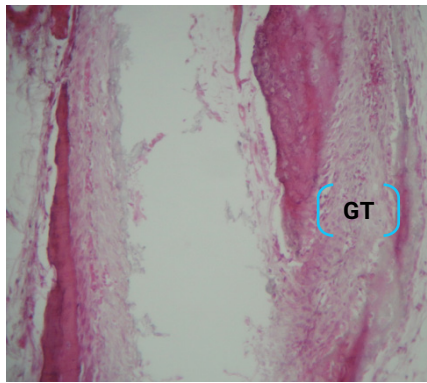


Figure 4. Biopsy of control (day 3) show moderate amount of granulation tissue (GT) formation.

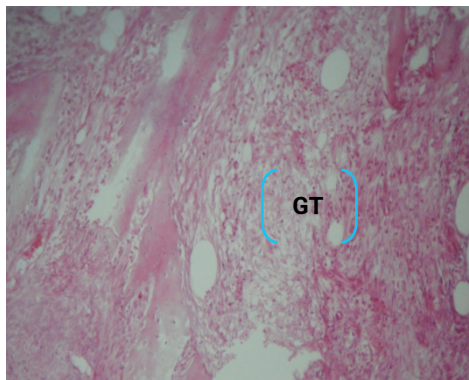


Figure 5. Biopsy of experimental group (day 3) show granulation tissue (GT) formation with many proliferating fibroblasts and few inflammatory cell infiltration.

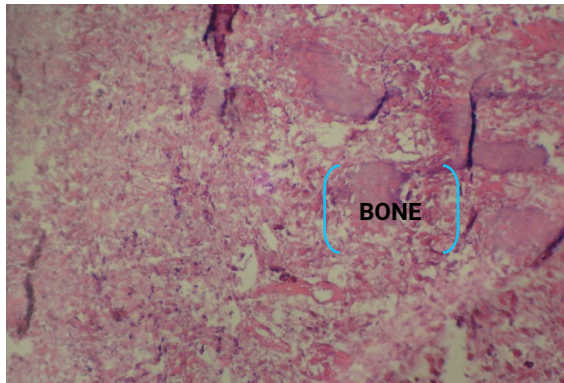


Figure 6. Biopsy of control group (day 7) show granulation tissue formation with new bone

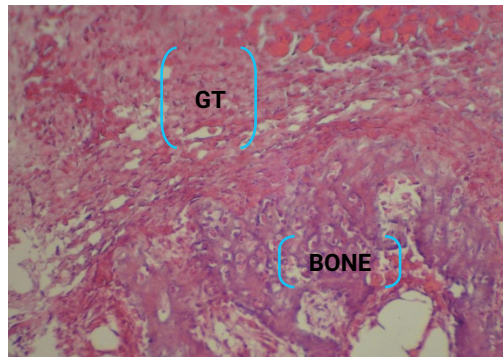

Figure 7. Biopsy of experimental group (day 7) show evidence of new bone formation with moderate amount of granulation tissue (GT).

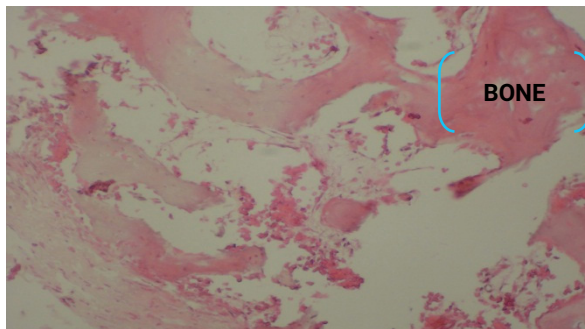


Figure 8. Biopsy of control group (day 14) show new bone trabeculae formation.

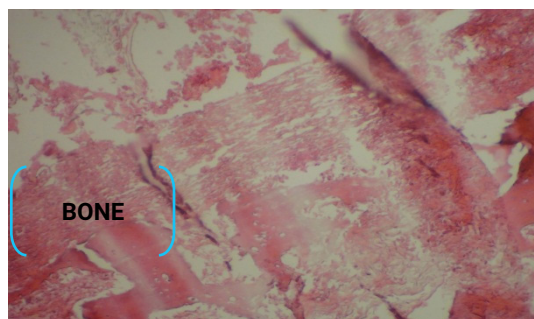

Figure 9. Biopsy of experimental group (day 14) show new bone formation.

Discussion

The maxillofacial bone skeleton is complex and delicate; thus, the healing and regeneration of the bone defects are challenging and have attracted much attention from many researchers who always try to develop many techniques and materials to achieve quick new bone formation and repair¹⁵. Several trials have been performed to regulate or decrease jaw bone resorption and activate new bone formation after dental extraction¹⁶. Natural herbs for healing of different illnesses in humans have been used in the ancient era; many herbs in nature were found to have magical properties for soft and hard tissue healing and repair by various mechanisms involve decontaminations, debridement and supply a wet atmosphere to provide a proper situation for natural healing processes¹⁷.

The anti-inflammatory effect of some natural herbs, such as *S. persica*, in in vitro models was discovered according to their cytotoxic activity against different cell lines grown¹⁸. Moreover, numerous researches have been carried out to investigate the therapeutic properties of *N. sativa* and it was found to have a wide range of activities¹⁶.

In our study, on day 1, the acute inflammatory reaction of the experimental group sections was lesser than that of the control group sections, which significantly decreased until the seventh day. This is usually related to the anti-inflammatory action of both *S. persica* and *N. sativa* mixture. This agree with Sardari et al.¹⁹ used different concentrations of miswak stick and leaves to assess their anti-inflammatory and cytotoxic activities. They reported that “*S. persica* inhibits IL-6 and IL-8 secretions by Jurkat cells”. Ezmirly et al.²⁰ and Hemati et al.²¹ also detected the anti-inflammatory effect of this herb. Moreover, the analgesic and anti-inflammatory effects of miswak were evaluated by Ahmad et al.²² by administering it orally to mice; they reported significant analgesic and dose-dependent anti-inflammatory activities of miswak. Pop et al.²³ assessed the *N. sativa* oil’s (NSO) anti-inflammatory, analgesic, and antioxidant activities in acute and sub-acute inflammation in rats and found that a high dose of NSO had an analgesic–anti-inflammatory effect similar to diclofenac in acute or chronic inflammation. Our results are consistent with Dwita et al.²⁴ study that revealed that the topical use of *N. sativa* was effective for both acute and sub-acute inflammation, and Pise and Padwal et al.²⁵.

In the present study, the amount of GT formation was noted to be greater in the experimental group along the different time periods, which is in line with the findings of Al-Bayaty et al.²⁶ who compared the ethanol and aqueous extract of *S. persica* in gel form that was applied to treat the socket after dental extraction with a control group (empty socket) in rats and evaluated the healing process histologically. They found that the socket treated with the aqueous extract of *S. persica* showed fibrous GT formation with osteoclast-like cells after 1 week, whereas the control group sockets were filled with fibrinous blood clots and juvenile fibrovascular GT. Moreover, Dwita et al.²⁴ demonstrated *N. sativa*'s beneficial role in improving the blood flow. Akhtar et al.²⁷ studied the effects of *N. sativa* in fracture defects in rats and revealed that it increased the blood supply to the fracture or defect area, thereby increasing angiogenesis; this increase in GT formation is important for fracture healing.

Al Bayaty et al.²⁶ studied the impact of *S. persica* in alveolar bone healing after a dental extraction in rats and found that, in 14 days, the sockets treated by the gel with ethanol miswak extract was filled with a more organized woven bone and the amount of mature bone was significantly greater as compared to the control group. More trabecular bone production with osteoblast cells were also noted in the experimental group, demonstrating rapid healing, as compared to the control group. Thus, the miswak gel promotes bone repair acceleration, consistent with our study findings in which the new bone formation appeared as a woven bone after 1 week in the experimental group. After 2 weeks, both the experimental and control groups showed an increased amount of new bone that appeared as woven and lamellar bone. This goes with both Guglielmotti et al.²⁸ stated that. at 14 days after extraction in rats, the *S. persica* group had the highest bone construction rate with a maximum alveolar volume. And, Dorri et al.²⁹ compared the use of chlorhexidine, tap water, and *S. persica* mouthwashes after tooth extraction in rats and found that. at 14 days, the *S. persica* group showed epithelialization, intertrabecular connective tissue growth and maturation, and subperiosteal bone creation; SP has the ability to initiate wound healing in the socket after tooth removal.

Al-Mutheffer³⁰ used NSO topically on the skin of rabbits and estimated the percutaneous effect of oil on bone healing; the histopathological assessment revealed that the bone healing process of the bone defect was initiated early on the 1st week until the 5th week in comparison with that of the control group. The oil extract of NS enhances bone healing by activating cell migration and differentiation, extracellular matrix formation, and organization toward calcification. Moreover, Abd Elrahman et al.¹ assessed the biological consequence of *N. sativa* on socket healing in rabbits. She extracted the lower first molar bilaterally and filled one of them with *N. sativa* while leaving the other empty as a control; after 2 weeks, the histological examination of the study group sockets revealed a highly vascular bone marrow and active bone formation with thicker bony trabeculae. These results could be related to the active ingredients of black seed such as amino acids, protein, fatty acids, vitamins, and minerals, especially (calcium)³¹. Another interesting component of *N. sativa* is TQ. Many trials have been performed to detect the influence of *N. sativa* or it is a major element of the essential oil (TQ) and found that majority of the pharmacological activities of *N. sativa* is due to

the presence of TQ, which has valuable effects on osteoporosis. A great number of bone progenitor cells that are histologically significant to the groups treated by *N. sativa* extracts having TQ matched that of the control groups on day 14⁹. Arslan et al.³² also assessed the histopathological effect of systemically applied TQ on the healing of bone defects in rat tibia and showed that the TQ-administered groups displayed high capillary intensity with bone formation in the defect area than the control group; TQ was found to enhance new bone formation in rats and could be used to accelerate bone healing.

Conclusion

The mixture of *S. persica* and *N. sativa* has an anti-inflammatory effect and accelerates bone healing by stimulating bone formation in the tooth extraction socket.

Acknowledgement

All authors thank the affiliates of the College of Dentistry in Mosul University.

Conflict of interest

All Authors declare no conflict of interest.

Data Availability

Datasets related to this article will be available upon request to the corresponding author.

Authors Contribution

Ali Idrees Al-Niimi: concept and clinical work, Noor A. Sulaiman: manuscript writing, editing, Huda A. Salim: manuscript supervision. Faris Ghanim Ahmed Al-Taee: Data Analysis. All Authors have revised and approved the final version of the manuscript.

References

1. Abd Elrahman S, Younes S, Kawana K. Evaluation of nigella sativa on socket healing in rabbits. *Alex Dent J*. 2019 Dec;44(3):60-4. doi: 10.21608/adjalexu.2019.63559.
2. Peck MT, Marnewick J, Stephen L. Alveolar ridge preservation using leukocyte and platelet-rich fibrin: a report of a case. *Case Rep Dent*. 2011;2011:345048. doi: 10.1155/2011/345048.
3. Chen ST, Buser D. Clinical and esthetic outcomes of implants placed in postextraction sites. *Int J Oral Maxillofac Implants*. 2009;24 Suppl:186-217.
4. Jamjoom A, Cohen RE. Grafts for ridge preservation. *J Funct Biomater*. 2015 Aug 7;6(3):833-48. doi: 10.3390/jfb6030833.
5. Nordin A, Bin Saim A, Ramli R, Abdul Hamid A, Mohd Nasri NW, Bt Hj Idrus R. Miswak and oral health: An evidence-based review. *Saudi J Biol Sci*. 2020 Jul;27(7):1801-10. doi: 10.1016/j.sjbs.2020.05.020.

6. Fouda AM, Youssef AR. Antiosteoporotic activity of *Salvadora persica* sticks extract in an estrogen deficient model of osteoporosis. *Osteoporos Sarcopenia*. 2017 Sep;3(3):132-7. doi: 10.1016/j.afos.2017.07.002.
7. Kumari A, Parida AK, Rangani J, Panda A. Antioxidant activities, metabolic profiling, proximate analysis, mineral nutrient composition of *salvadora persica* fruit unravel a potential functional food and a natural source of pharmaceuticals. *Front Pharmacol*. 2017 Feb;8:61. doi: 10.3389/fphar.2017.00061.
8. Mekhemar M, Geib M, Kumar M, Radha, Hassan Y, Dörfer C. *Salvadora persica*: nature's gift for periodontal health. *Antioxidants (Basel)*. 2021 Apr;10(5):712. doi: 10.3390/antiox10050712.
9. Santoso A.R.B, Huwae TECJ, Kristianto Y, Putera MA. Effect of thymoquinone: the extract of *nigella sativa* in accelerating soft callus formation in fracture, *Int J Res Med Sci*. 2019 Nov;7(11):4068-72. doi: 10.18203/2320-6012.ijrms20194969 .
10. Hussein El-Tahir KED, Bakeet DM. The black seed *nigella sativa* linnaeus - a mine for multi cures: a plea for urgent clinical evaluation of its volatile oil. *J Taibah Univ Med Sci*. 2013;1(1): 1-19. doi: 10.1016/s1658-3612(06)70003-8.
11. Paknejad M, Rokn AR, Eslami B, Afzalifar R, Safiri A. Evaluation of three bone substitute materials in the treatment of experimentally induced defects in rabbit calvaria. *Front Dent*. 2007;4(4):171-5.
12. Kilic N. A Comparison between Medetomidine- Ketamine and Xylazine- Ketamine Anaesthesia in Rabbits. *Turk J Vet Anim Sci*. 2004;28(5):921-6.
13. Lester SC. *Manual of surgical pathology*. 3rd ed. Philadelphia: Saunders Elsevier; 2010.
14. Lucaciu O, Gheban D, Sorițau O, Băciuț M, Câmpian RS, Băciuț G. Comparative assessment of bone regeneration by histometry and a histological scoring system. *Rev Rom Med Lab*. 2015;23(1):31-45. doi: 10.1515/rrlm-2015-0009.
15. Ezirganli S, Kazancioglu HO, Ozdemir H, Inan DS, Tek M. The Effects of *nigella sativa* seed extract on bone healing in an experimental model. *J Craniofac Surg*. 2016 Oct;27(7):1905-9. doi: 10.1097/SCS.0000000000002986.
16. Goreja WG. *Black Seed: Nature's Miracle Remedy*. New York: Amazing Herbs Press; 2003.
17. Tatke P, Nehete M, Gabhe S. Antioxidant, antimicrobial and wound healing activity of *salvadora persica* twig extracts. *J Complement Med Alt Healthcare*. 2018;7(4):555720. doi: 10.19080/JCMAH.2018.07.555720.
18. Ibrahim A, El-Gengaihi S, Motawe H. Phytochemical and cytotoxicity investigations of *Salvadora persica* bark extracts. *J Arab Soc Med Res*. 2011;6:127-33.
19. Sardari F, Kazemi Arababadi M, Heiranizade M, Mosadeghi, M. Anti-inflammatory and cytotoxicity effects of *Salvadora persica* (meswak) extracts on jurkat t-cells. *J Microbiol Biotechnol Food Sci*. 2015;4(5):379-82. doi:10.15414/jmbfs.2015.4.5.379-382.
20. Ezmirly ST, Cheng JC, Wilson SR. Saudi Arabian medicinal plants: *Salvadora persica*. *Planta Med*. 1979 Feb;35(2):191-2. doi: 10.1055/s-0028-1097205.
21. Hemati K, Mehrzadi S, Bakhtiarian A, Motevalian M, Nikouei V, Foroohandeh M, et al . Miswak sticks' extract anti-inflammatory properties in carrageenan test. *Razi J Med Sci*. 2019;25(10):38-45.
22. Ahmad M, Imran H, Yaqeen Z, Rehman Z, Rahman A, Fatima N, et al. Pharmacological profile of *Salvadora persica*. *Pak J Pharm Sci*. 2011 Jul;24(3):323-30.
23. Pop RM, Sabin O, Suciuc Ș, Vesa SC, Socaci SA, Chedea VS, et al. *Nigella sativa*'s anti-inflammatory and antioxidative effects in experimental inflammation. *Antioxidants (Basel)*. 2020 Sep;9(10):921. doi: 10.3390/antiox9100921.
24. Dwita LP, Yati K, Gantini SN. The anti-inflammatory activity of *nigella sativa* balm sticks. *Sci Pharmac*. 2019;87(3):1-7. doi: 10.3390/scipharm87010003.

25. Pise HN, Padwal SL. Evaluation of anti-inflammatory activity of *Nigella sativa*: an experimental study. *Natl J Physiol Pharm Pharmacol*. 2017;7(7):707-11. doi: 10.5455/njppp.2017.7.0204705032017.
26. Al Bayaty FH, Zaidi WIW, Abdullah MNS, Emad O, Al-Obaidi MMJ. Effect of *Salvadora Persica* (Miswak) on alveolar bone healing after tooth extraction in rat. *J Int Dent Med Res*. 2018 Sep 1;11(3):770-7.
27. Akhtar M, Maikiyo AM, Khanam R, Mujeeb M, Aqil M, Najmi AK. Ameliorating effects of two extracts of *Nigella sativa* in middle cerebral artery occluded rat. *J Pharm Bioallied Sci*. 2012 Jan;4(1):70-5. doi: 10.4103/0975-7406.92740.
28. Guglielmotti MB, Ubios AM, Cabrini RL. Alveolar wound healing alteration under uranyl nitrate intoxication. *J Oral Pathol*. 1985 Aug;14(7):565-72. doi: 10.1111/j.1600-0714.1985.tb00530.x.
29. Dorri M, Shahrabi S, Navabazam A. Comparing the effects of chlorhexidine and persica on alveolar bone healing following tooth extraction in rats, a randomised controlled trial. *Clin Oral Investig*. 2012 Feb;16(1):25-31. doi: 10.1007/s00784-010-0474-y.
30. Al-Mutheffer E. The percutaneous effect of black seed (*Nigella sativa*) oil as external topical treatment on bone healing in rabbits. *AL-Qadi J Vet Med Sci*. 2014;13(2):146-54.
31. Nickavar B, Mojab F, Javidnia K, Amoli MA. Chemical composition of the fixed and volatile oils of *Nigella sativa* L. from Iran. *Z Naturforsch C J Biosci*. 2003 Sep-Oct;58(9-10):629-31. doi: 10.1515/znc-2003-9-1004.
32. Arslan AH, Tomruk CÖ, Meydanlı EG, Özdemir İ, Duygu Çapar G, Kütan E, et al. Histopathological evaluation of the effect of systemic thymoquinone administration on healing of bone defects in rat tibia. *Biotechnol Biotec Eq*. 2017;31:175-8. doi: 10.1080/13102818.2016.1257925.