



# Demineralized freeze-dried bone allograft with/without i-Platelet-rich fibrin in 3 wall intrabony defects

Rinnu Mathew<sup>1</sup> , Anuradha Bhatsange<sup>2\*</sup> 

<sup>1</sup> Former Post Graduate Student, Department of Periodontics, JMF's ACPM Dental college, Sakri Road, Dhule, Maharashtra, India.

<sup>2</sup> Professor, Department of Periodontics, JMF's ACPM Dental college, Sakri Road, Dhule, Maharashtra, India.

**Corresponding author:**

Anuradha Bhatsange  
Professor, Dept. of Periodontics,  
JMF's ACPM Dental college  
JMF's ACPM dental college,  
Sakri Road, Dhule, Maharashtra,  
India, 424001.  
Phone numbers: 9960881275;  
E-mail: anujaps219@gmail.com

**Editor:** Altair A. Del Bel Cury

**Received:** July 15, 2022

**Accepted:** June 02, 2023



Demineralized freeze-dried bone allograft (DFDBA) contains bone morphogenetic proteins (BMPs), hence is osteoinductive. Autologous platelet concentrates exhibit a higher quantity of growth factors. Both these biomaterials aid in bone regeneration when placed in three-wall intrabony defects. However, their efficacy when used alone and in conjugation is not clear. **Aim:** To assess clinical and radiographic efficacy of injectable platelet-rich fibrin (i-PRF) with microsurgical access flap in the treatment of three-wall intrabony defects in chronic periodontitis patients. **Methods:** Thirty sites with three-wall intrabony defects were randomly assigned to control and test group by computer generated method. The test group obtained i-PRF mixed with DFDBA while the control group received only DFDBA. Clinical parameters such as site-specific Plaque index (PI), Radiographic intrabony defect depth (IBDD), modified-Sulcular bleeding index (mSBI), Clinical attachment level (CAL), and Probing pocket depth (PPD) were measured at baseline, three and six months. **Results:** Intragroup comparison within the control group and test group exhibited statistically highly significant variation of mean PI, mSBI, PPD, CAL, and IBDD score from baseline to 3 months and from 3-6 months ( $p < 0.001$ ). However, intergroup comparison demonstrated no statistically significant variation of mean IBDD at all 3 intervals ( $p > 0.05$ ). **Conclusion:** i-PRF combined with DFDBA enhanced the radiographic and clinical parameters as opposed to DFDBA alone. The role of i-PRF is promising in its capacity for easy obtainability and increased potential to aid in regeneration.

**Keywords:** Periodontitis. Allografts. Alveolar bone loss. Platelet-Rich Fibrin. Regeneration.

## Introduction

Regeneration of periodontium is a process of restoring the complete architecture and function of the periodontium<sup>1</sup>. It involves new functional periodontal attachment between newly formed bone and cementum<sup>1,2</sup>. The process constitutes a multi-dependent sequence of biological events including cell adhesion, migration, proliferation, and differentiation<sup>3</sup>.

Periodontitis is defined as an inflammatory disease of the supporting structural apparatus resulting in progressive destruction of the “periodontal ligament”, alveolar bone with pocket formation, recession, or both. Bone loss that occurs as a consequence of this inflammatory disease results in different patterns and in various combinations. The vertical/ angular defects that occur in an oblique direction, with a hollow trough in the bone alongside the root with base located apical to the surrounding bone is termed as intrabony defect<sup>4</sup>. These defects when surrounded by two or three walls become more amenable to regeneration as it provides the best spatial relationship for defect bridging by providing vascular and cellular elements from the periodontal ligament and adjacent osseous wall<sup>5</sup>. Although various attempts to accomplish goals of regeneration have been tried using bone grafts, [autografts, allografts, xenografts, alloplasts] membranes, polypeptide growth factors, tissue engineering applications etc, reconstruction of fully functioning periodontium still remains a big challenge despite the advances. “Demineralized freeze-dried bone allograft” (DFDBA) a widely used allograft, exhibits osteoinductive and osteoconductive properties owing to its content of bone morphogenetic proteins<sup>2</sup>. These proteins orchestrate mesenchymal cell migration, new attachment, and osteogenesis that help to regenerate cementum, bone, and periodontal ligament with histological evidence<sup>6</sup>. However the amount of bone fill found with the use of DFDBA has not been very clear. Hence, in the quest to enhance the efficacy of periodontal regeneration with various bone grafts, polypeptide growth factors derived from the autologous blood concentrates in the form of “platelet-rich plasma” (PRP) and “platelet-rich fibrin” (PRF) have been used. These show the ability to induce cell proliferation and differentiation and osteoinduction. The initial biochemical analysis of PRF composition indicated it to be an intimate assembly of cytokines, glycanic chains, and structural glycoproteins enmeshed within a slowly polymerized fibrin network<sup>7</sup>. Later on the use of PRF membrane has been shown to exhibit a significant but, slow sustained release of key “growth factors” for  $\geq 1$  week and  $\leq 28$  days, suggesting its ability to stimulate its environment for wound healing<sup>8</sup>. However, another form of PRF, i.e. an injectable form of PRF (i-PRF) demonstrated good results with higher concentration of stem cells and better potential for regeneration due to its capacity of inducing higher cell migration and mRNA expression of “Transforming growth factor-beta” (TGF- $\beta$ ), “platelet derived growth factor” (PDGF), and collagen<sup>1</sup>. The property of i-PRF forming a hydrogel even after 10 days hypothesized it to release additional growth factors<sup>9</sup>.

Good and predictable outcomes of regenerative procedures are accomplished by incorporation of microsurgery applications too. Microsurgery refers to refinement in surgical technique with vision enhancement through magnification and

was introduced to the speciality of Periodontics in 1992<sup>10</sup>. Periodontal microsurgery helps to: 1) improve tissue preservation and better handling of specific flap designs to access the defects; 2) optimize defect debridement and root instrumentation; 3) ensure optimal delivery of the regenerative technology; 4) optimize flap mobility to achieve primary closure of the interdental space<sup>11</sup>. Its application promises to change clinical concepts of periodontal surgical care by improvement in predictability, cosmetic result and patient comfort level over conventional periodontal surgical procedures<sup>12</sup>. This implies placement of accurately mapped incisions, elevation of flap with minimal damage, precise wound closure without tension, resulting in reduction of postoperative morbidity. Rendering maximum benefit to the patient with advancements in the treatment aspects, and the best regenerative material available, the current study was carried out to explore the clinical and radiographic effectiveness of i-PRF combined with DFDBA by microsurgical access flap in the treatment of three-wall intrabony defects in patients with "chronic periodontitis".

## Material and methods

### Trial design and ethics approval

This was a randomized controlled clinico-radiographic study carried out in Dept. of Periodontology. A sample size of thirty sites were chosen to employ statistical software, projected by evaluating the prior literature performed in the field of research and maintaining the confidence interval at 95% with a relative precision of 20%. The study was approved by institutional review board.

### Participants

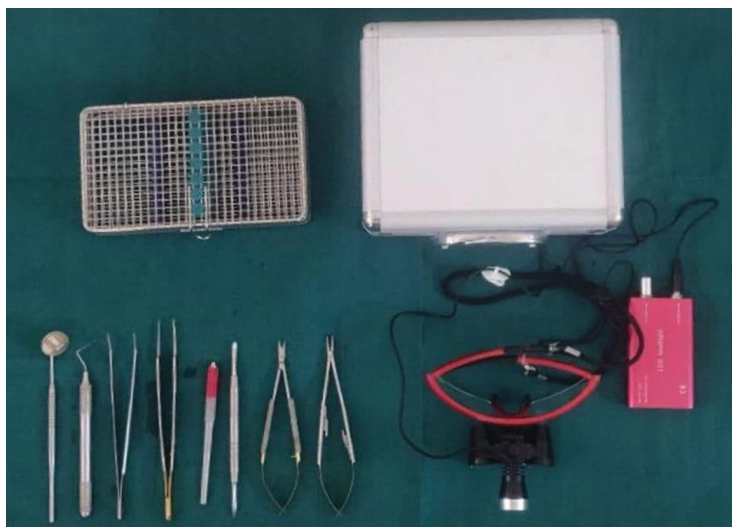
Sixty-one patients were recruited from out-patient department and assessed for eligibility. Out of these 31 patients were excluded as they did not meet the inclusion criteria. Chronic periodontitis patients between 30-50 years of age with 30 sites exhibiting 3 wall intrabony defects >3mm deep (the distance among defect base and alveolar crest on an "Intraoral Periapical Radiograph" (IOPA) combined with an interproximal residual Probing Pocket Depth (PPD) >5mm were included. Patients diagnosed with aggressive periodontitis, systemic illnesses, insufficient platelet count, pregnant/lactating mothers, postmenopausal women, and smokers, on a therapeutic regimen were excluded.

### Intervention

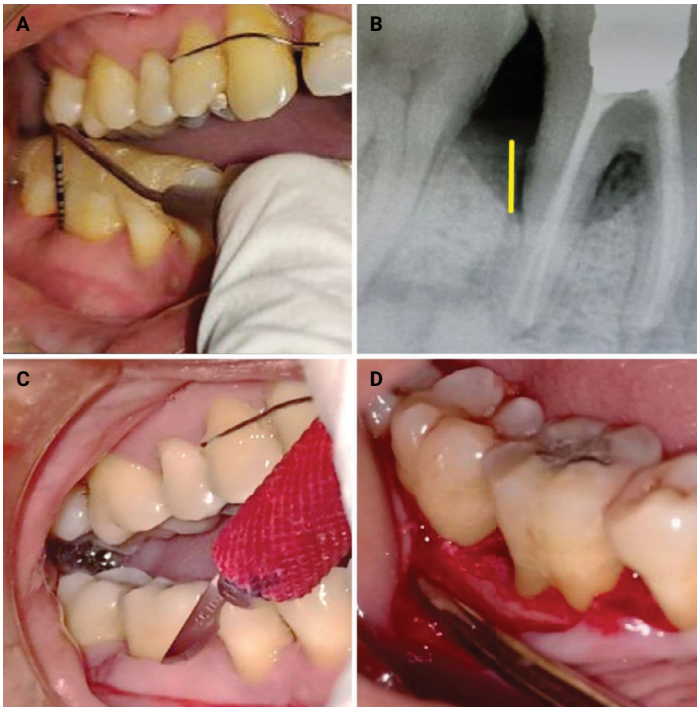
After obtaining consent from the participants following clinical parameters were recorded "Plaque Index" (PI)<sup>13</sup>, and "Modified Sulcus Bleeding Index" (mSBI)<sup>14</sup>. The PPD and "Clinical Attachment Level" (CAL) were recorded with "University of North Carolina-15" (UNC-15) periodontal probe along with an acrylic stent from marginal gingiva to the depth of the pocket and from "cemento-enamel junction" (CEJ) to the depth of pocket respectively. Radiographic assessment of IBDD was carried out using a computer running Windows XP with 'Kodak RVG 5000 digital radiography program. Standardized paralleling techniques were used for radiographs. IBDD was

evaluated using Digimizer software. where the resolution of the image was set at a value where each pixel was equal to 0.026mm. The defect depth was computed from the alveolar crest to its base. The readings obtained in pixels were converted to mm by multiplying the pixel with 0.026.

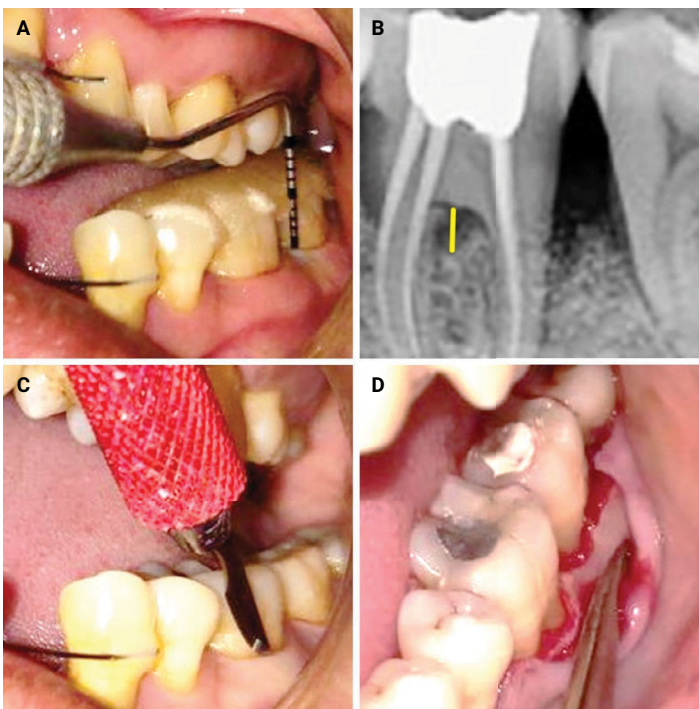
The DFDBA's particle size used was 500 $\mu$ m and obtained from Tata memorial centre, Kharghar, Navi Mumbai. Four weeks following phase I therapy, the selected operative site was anaesthetized with 2% lignocaine hydrochloride using adrenaline (1:80000) and a microsurgical flap for access was planned with microsurgical instruments (Figure 1). Using 3.5 $\times$ optical magnification dental loupes, buccal & lingual sulcular incisions were made using microsurgical ophthalmic blades. Reflection of the mucoperiosteal flap was carried out using the microsurgical periosteal elevator at the test site and control site maintaining as much interproximal soft tissue as possible. (Figure 2, 3a,b,c,d.) Meticulous defect debridement as well as root planning were performed with specific curettes. The preparation for i-PRF was carried out with specifications as described<sup>15</sup>. Upon termination of centrifugation, the upper orange colour fluid was collected using a 5ml syringe with a 26G needle (Figure 4a,b,c,d). After 5 minutes DFDBA particles were added to i-PRF in a 1:1 ratio and within 15 minutes the material was ready to use with a total working time of 20 minutes. The mixture was delivered to the test site with the help of a bone graft carrier followed by sutures and placement of periodontal dressing. (Figure 5a,b,c,d). The control group received DFDBA granules mixed with saline in the same proportion. The mucoperiosteal flaps were stabilized using 5-0 sutures. A periodontal dressing was used to protect the surgical area (Figure 6).



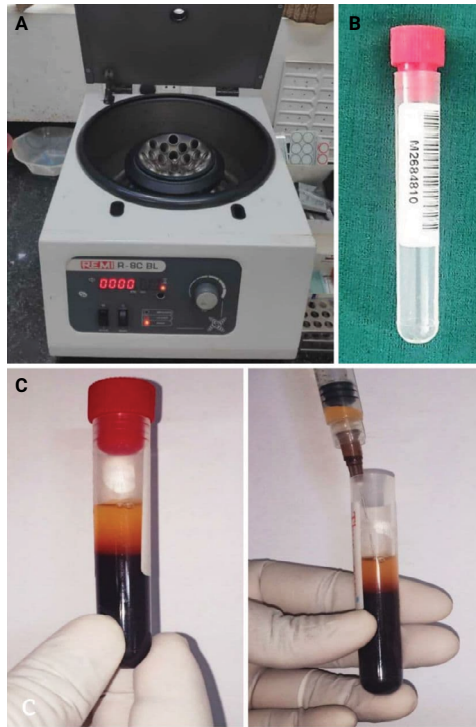
**Figure 1.** Microsurgical instruments with magnifying loupes.



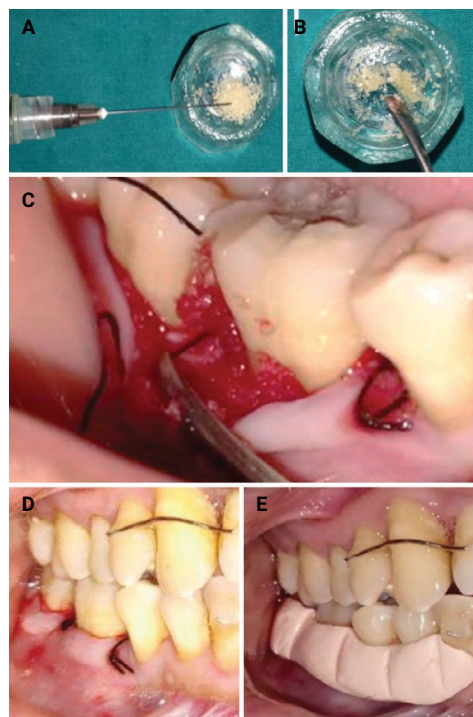
**Figure 2.** Preoperative view showing. a) probing depth assessment b) intrabony defect on Digimiser c) placement of the incision d) Flap reflection.



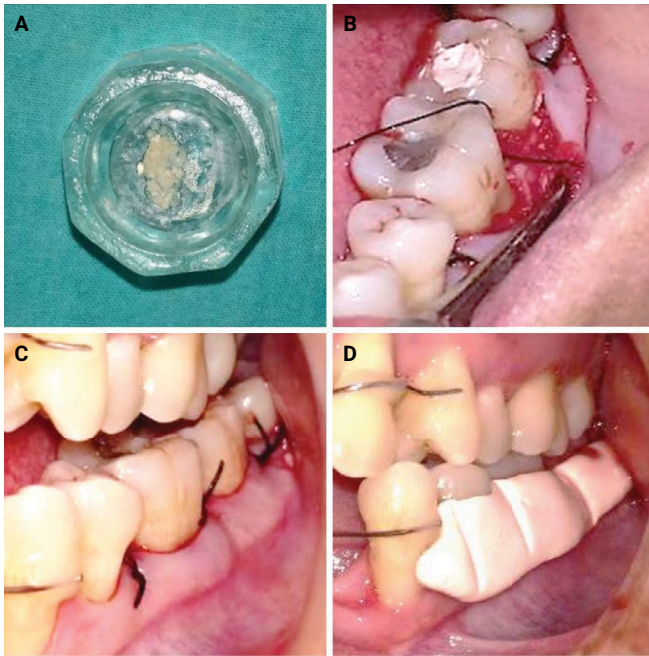
**Figure 3.** The clinical picture at the control site showing a) probing depth assessment at baseline b) Digimiser showing intrabony defect c) Placement of sulcular incision with microblade d) Flap reflection.



**Figure 4.** Clinical picture showing i-PRF preparation. a) Centrifuge machine b) Vacutainer c) Obtention of i-PRF d) Loading of i-PRF in syringe.

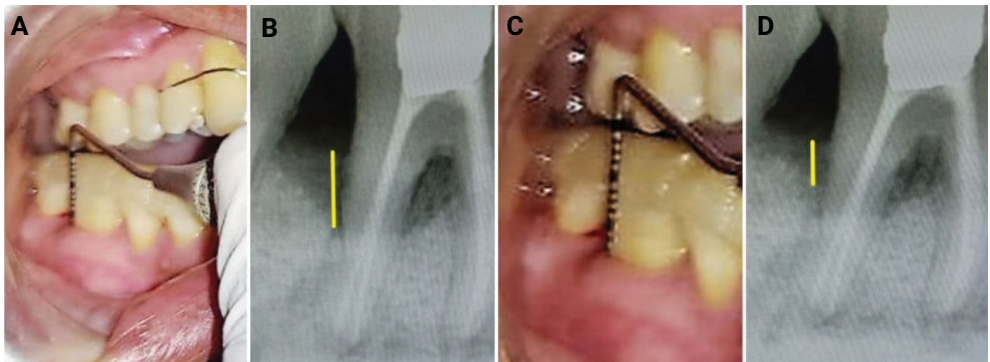


**Figure 5.** Clinical picture showing a) i-PRF delivery into DFDBA b) Mixing of i-PRF and DFDBA c) Grafting at the test site d) Placement of sutures e) Periodontal dressing.

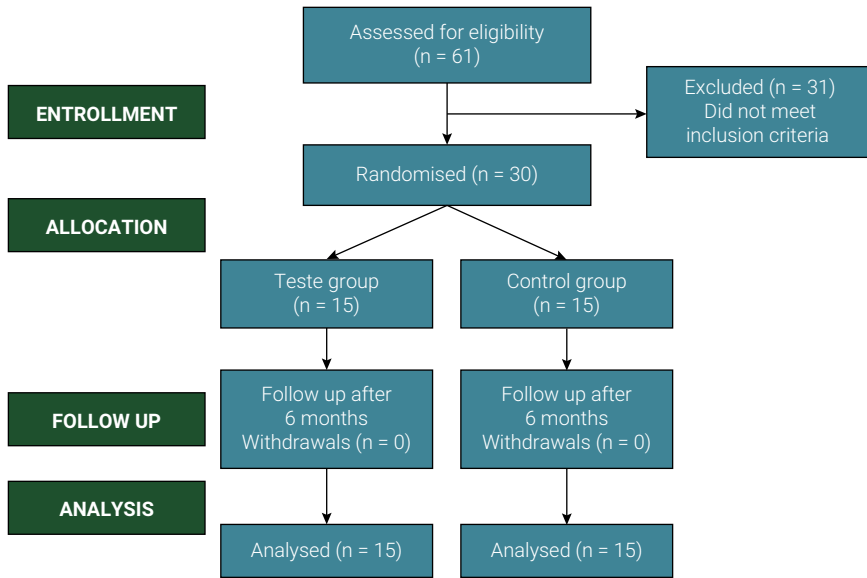


**Figure 6.** The clinical picture at the control site showing a) DFDBA b) Grafting c) Placement of sutures d) Periodontal dressing.

The sutures were removed after 10 days. A complete re-evaluation of all the clinical and radiographical parameters at the 3<sup>rd</sup> and 6<sup>th</sup> months post-surgically was undertaken (Figure 7a,b,c,d).



**Figure 7.** Postoperative view showing clinical and Digimiser picture at 3 months (a,b) and at 6 months (c,d) at test site showing probing depth assessment and intrabony defect resolution.



**Figure 8.** CONSORT statement for study description.

## Randomization

Randomization was carried out using computer generated numbers and were allocated to test and control group.

## Statistical method

Data measurements were determined at baseline, three, and six months. The parametric tests were applied to analyse the data statistically. Statistics were accepted as significant at values of  $p < 0.05$ . Data was provided as descriptive statistics by minimum, maximum range, mean and standard deviation. Intragroup comparison of mean difference of normally distributed variables was analysed using the ANOVA test. Pairwise comparison was done using the Bonferroni Post Hoc test. Intergroup comparison of non-normally distributed variables was done with “Mann Whitney U-test” & an unpaired t-test. The “Statistical Package for the Social Sciences” (SPSS) version 19 was applied to conduct the statistical analysis.

## Results

Sixty-one patients were assessed for eligibility out of which 31 were excluded as they did not meet the inclusion criteria. Thirty sites evaluated in thirty patients out of which 15 sites each were randomly allocated to test and control group. Intragroup comparison within the test and control group presented statistically highly substantial variation of mean site-specific PI, modified SBI, PPD, CAL, and IBDD score during different durations that is from baseline to 3 months & from 3 to 6 months ( $p < 0.001$ ) [Table 1 and 3]. Similar results were obtained with pairwise comparisons within the two groups at ( $p < 0.001$ ) [Table 2, 4]. The inter-group comparison revealed no statistically substantial variation of mean site-specific PI at baseline, 3, and 6 months ( $p > 0.05$ ). The scores of mSBI at 3



months showed statistically significant variation ( $p < 0.05$ ), but not at 6 months ( $p > 0.05$ ). The assessment of PPD and CAL revealed statistically no significant ( $p > 0.05$ ) variation at baseline and six months but in 3<sup>rd</sup> month, the test group presented a greater reduction in PPD and higher gain in attachment than the control group which was statistically significant ( $p < 0.05$ ). Regarding IBDD, there was statistically no significant variation of mean intra bony depth defect at all 3 intervals between the test & control group ( $p > 0.05$ ) [Table 5]. A change and a comparison of the change in PI, mSBI, PPD, CAL, and IBDD from baseline to six months in between the 2 groups was compared with the “Mann-Whitney U test” which revealed that there was statistically no significant ( $p > 0.05$ ) variation of mean changes at six months as depicted. [Table 6 and 7]

**Table 1.** Intragroup comparison of PI, mSBI, CAL, PPD, IBDD score at baseline, 3- and 6-months interval in Test group.

PARAMETERS	BASELINE	3 MONTHS	6 MONTHS	SUM OF SQUARES	MEAN SQUARE	F	P VALUE
PI	2.80±0.41	1.73±.458	0.87±.352	28.133	14.067	75.74	<0.001
mSBI	2.73±.458	1.13±.352	0.67±.488	32.044	16.022	60.807	<0.001
PPD	8.00±2.138	4.40±1.056	1.87±1.407	284.978	142.489	55.757	<0.001
CAL	6.27±1.831	2.80±1.320	0.47±.516	255.511	127.756	71.480	<0.001
IBDD	5.07±0.80	3.20±.86	1.67±.61	86.978	43.489	117.5889	<0.001

IBDD-Intrabony defect depth, “CAL-Clinical attachment level, PPD-Probing Pocket Depth”, mSBI-modified Sulcus Bleeding Index, F-ANOVA Test, PI-Plaque Index, P-Probability value. ( $p < 0.05$ )

**Table 2.** Pairwise difference of PI, mSBI, CAL, PPD, and IBDD at baseline, 3 to 6 months interval in the Test group.

PARAMETERS	MEAN DIFFERENCE		
	BASELINE-3 MONTH	BASELINE-6 MONTH	3-6 MONTHS
PI	1.07	1.93	.867
mSBI	1.600*	2.067*	.467*
PPD	3.600*	6.133*	2.533*
CAL	3.467*	5.800*	2.333*
IBDD	1.87	3.40	1.53

PPD-Probing Pocket Depth, mSBI- “modified Sulcus Bleeding Index, CAL-Clinical attachment level,” PI-Plaque Index, IBDD-Intrabony defect depth. ( $p < 0.05$ )

**Table 3.** Intragroup comparison of PI, mSBI, CAL, PPD, IBDD score at baseline, 3 months 6 months in the test group.

PARAMETERS	BASELINE	3 MONTHS	6 MONTHS	SUM OF SQUARES	MEAN SQUARE	F	P VALUE
PI	2.60±0.51	1.60±.507	.60±.507	30.000	15.000	58.333	<0.001
mSBI	2.47±.516	1.47±.516	.40±.507	32.044	16.022	60.807	<0.001
PPD	7.00±1.648	3.67±.724	1.27±1.100	248.711	124.356	83.880	<0.001
CAL	5.07±1.438	1.80±.676	.27±.458	180.311	90.156	98.951	<0.001
IBDD	4.53±.640	2.93±.704	1.27±.704	80.044	40.022	85.762	<0.001

PPD-Probing Pocket Depth, mSBI- “modified Sulcus Bleeding Index, CAL-Clinical attachment level”, PI-Plaque Index, IBDD-Intrabony defect depth. ( $p < 0.05$ ).

**Table 4.** Pairwise difference of PI, mSBI, CAL, PPD, and IBDD in between baseline, 3 & 6months intervals in the control group.

PARAMETERS	MEAN DIFFERENCE		
	"BASELINE-3 MONTH	BASELINE-6 MONTH	3 MONTH-6 MONTHS"
PI	1.000*	2.000*	1.000*
mSBI	1.000*	2.067*	1.067*
PPD	3.333*	5.733*	2.400*
CAL	3.267*	4.800*	1.533*
IBDD	1.600*	3.267*	1.667*

PPD-Probing Pocket Depth, m SBI-modified Sulcus Bleeding Index, CAL-Clinical attachment level, PI-Plaque Index, IBDD-Intrabony defect depth. (p<0.05).

**Table 5.** Intergroup comparison of PI, mSBI, CAL, PPD, and IBDD at baseline, 3 & 6 months.

PARAMETERS	BASELINE		3 MONTHS		6 MONTHS	
	TEST GROUP	CONTROL GROUP	TEST GROUP	CONTROL GROUP	TEST GROUP	CONTROL GROUP"
PI	2.80±0.41	2.60±0.51	1.73±.458	1.60±.507	.87±.352	.60±.507
mSBI	2.73±.458	2.47±.516	1.13±.352	1.47±.516	.67±.488	.40±.507
PPD	8.00±2.138	7.00±1.648	4.40±1.056	3.67±.724	1.87±1.407	1.27±1.100
CAL	6.27±1.831	5.07±1.438	2.80±1.320	1.80±.676	.47±.516	.27±.458
IBDD	5.07±0.80	4.53±.640	3.20±.862	2.93±.704	1.67±.617	1.27±.704

PPD-Probing Pocket Depth, m SBI-modified Sulcus Bleeding Index, CAL-Clinical attachment level, PI-Plaque Index, IBDD-Intrabony defect depth. (p<0.05).

**Table 6.** Change in Pi, SBI, PPD, and IBD from baseline to 6 months between the 2 groups.

By 6 months Change in	Group	Minimum	Maximum	Mean	Std. Deviation
PI	Test	1	3	1.93	.060
	Control	1	3	2.00	.37
SBI	Test	1	3	2.07	.46
	Control	1	3	2.07	.45
PPD	Test	2	10	6.13	2.4
	Control	3	9	5.73	1.8
CAL	Test	3	9	5.80	1.82
	Control	2	8	4.80	1.56
IBD	Test	2	6	3.40	0.91
	Control	3	4	3.27	.45

m SBI-modified Sulcus Bleeding Index, PPD-Probing Pocket Depth, CAL-Clinical attachment level, PI-Plaque Index, IBDD-Intrabony defect depth. (p<0.05).

**Table 7.** Comparison of change in PI, mSBI, PPD, and IBD from baseline to six months between the 2 groups.

	Six months PI change	Six months mSBI change	Six months of PPD change	Six months CAL change	Six months IBDD change
Mann-Whitney U	105.500	112.500	104.000	82.500	104.50
Z-score	-.448	.000	-.360	-1.271	-0.379
P value	.654	1.000	.719	.204	.704

PPD-Probing Pocket Depth, m SBI-modified Sulcus Bleeding Index, CAL-Clinical attachment level, PI-Plaque Index, IBDD-Intrabony defect depth. Z-score. ( $p < 0.05$ ).

## Discussion

The primary purpose of periodontal therapy is resolution of inflammation, elimination of infection, disease progression cessation, and prevention of recurrence<sup>16</sup>. DFDBA was chosen in this study due to its inductive properties of stimulating host stem cells to differentiate into osteoblasts. Its regenerative properties have stimulated physicians to broadly utilize it in infrabony defects<sup>17</sup>. In addition DFDBA has been shown to withstand displacement due to its physical property<sup>2</sup>.

Platelet concentrates possess growth factors that act as vital modulators inducing the differentiation, proliferation, attachment, and migration of periodontal progenitor cells<sup>5</sup>. Advantages of using platelet concentrates is its simpler preparation, inexpensive nature and antibacterial effect due to presence of leukocytes<sup>18</sup>. With the speculation, that the addition of autologous plasma derivatives like PRP, PRF, and i-PRF might show synergistic and predictable outcomes, this study combined these two biomaterials that is i-PRF and DFDBA. i-PRF can be employed to mix graft cohesively and sprayed over surgical sites due to its injectable form<sup>19</sup>. i-PRF remarkably influences osteoblast behaviour by impacting the migration, proliferation, and differentiation of human osteoblasts according to a study and has been shown to complement graft materials in aiding regeneration<sup>20,21</sup>. Taking into consideration the above aspects, the efficiency of i-PRF with DFDBA and DFDBA alone was tested clinically and radiographically. Assessment period of 6 months for evaluation of radiographs was chosen as evidence of rising bone density is frequently not observed until then<sup>1</sup>.

The clinical parameters studied were PI, mSBI, PPD, CAL and IBDD. PI showed statistically high significant difference between the three intervals in both groups depicting good plaque control which could be due to reinforcement of oral hygiene instructions. However intergroup comparison revealed no statistically substantial difference. This was in line with research conducted by Sharma and Pradeep<sup>22</sup>, Elgendy and Abp Shady<sup>20</sup> and Agarwal et al.<sup>5</sup>.

Modified SBI was recorded to assess the presence or absence of gingival inflammation. Both the groups showed a remarkable reduction in inflammation at various intervals. The outstanding potential of i-PRF being an anti-inflammatory has been highlighted due to its property of reducing proinflammatory M1 macrophage phenotype and activation of dendritic cells<sup>23</sup>.

PPD was used to evaluate the effectiveness of the therapy and a gain in the CAL remains the gold standard for evaluating the success of periodontal treatment. A reduction in PPD from baseline to six months was noted in the test and control group which was statistically highly significant. At 3 months, the test group fared better than the “control group” [ $p < 0.05$ ], but intergroup comparison however failed to reach a statistically significant difference at 6 months suggesting that i-PRF combined with DFDBA as well as DFDBA alone when used was effective in reducing the probing pocket depth.

Progressive improvement in the mean CAL from baseline to three months and from 3-6 months was observed which was highly significant in both groups. However intergroup comparison revealed no statistical significance. These outcomes were consistent with the research performed by Khosropanah et al.<sup>24</sup> and Agarwal et al.<sup>5</sup>. Gain in CAL is attributed to raised resistance to probing caused by a drop in inflammation, gingival fibers reformation, and a long junctional epithelium<sup>25</sup>.

In the current work, the mean IBDD in both groups from baseline to six months was statistically highly significant ( $p$ -value  $< 0.05$ ). Both the groups demonstrated a drop in defect depth with formation of new bone on the radiograph. Radiographically better bone fill was observed in the test group. This might be attributed to the addition of i-PRF with DFDBA. However, the test group failed to reach a statistically significant value. The outcomes are in line with the research performed by Agrawal et al.<sup>5</sup> and Khosropanah et al.<sup>24</sup>.

Refinements in surgical procedures have entailed use of the minimally invasive surgical method which create minimum flap reflection, minimal wounds, and gentle handling of the hard & soft tissues<sup>26</sup>. The benefits include better visual acuity, ease of soft tissue handling, and precise wound closure, enabling healing with primary intention<sup>27</sup>. In the present study, microsurgical flap access was employed that allowed a more accurate, less traumatic access to periodontal defect however no parameters were included to evaluate the impact of the microsurgical approach on the healing of the flap. Histologic analysis or surgical re-entry was not opted due to ethical reasons which were limitations of the study.

## Conclusion

In the current research, it may be inferred that DFDBA alone or in combination with i-PRF can be used to treat 3-walled intrabony defects. Thus, the future scope of the study includes exploring i-PRF's potential to be used for its anti-inflammatory property in conjunction with other bone graft materials for which more longitudinal studies are required.

## Funding

None.

## Conflicts of interest

None.

## Authors' Contribution

All authors actively participated in the discussion of the manuscript's findings and have revised and approved the final version of the manuscript.

## Data availability

Datasets related to this article will be available upon request to the corresponding author.

---

### References:

1. Brunsvold MA, Mellonig JT. Bone grafts and periodontal regeneration. *Periodontol* 2000. 1993 Feb;1:80-91.
2. Zhou S, Sun C, Huang S, Wu X, Zhao Y, Pan C, et al. Efficacy of adjunctive bioactive materials in the treatment of periodontal intrabony defects: a systematic review and meta-analysis. *Biomed Res Int*. 2018 May;2018:8670832. doi: 10.1155/2018/8670832.
3. Panda S, Ramamoorthi S, Jayakumar ND, Sankari M, Varghese SS. Platelet rich fibrin and alloplast in the treatment of intrabony defect. *J Pharm Bioallied Sci*. 2014 Apr;6(2):127-31. doi: 10.4103/0975-7406.129178.
4. Prichard JF. The etiology, diagnosis and treatment of the intrabony defect. *J Periodontol*. 1967 Nov-Dec;38(6):455-65. doi: 10.1902/jop.1967.38.6\_part1.455.
5. Agarwal P, Chatterjee A, Gokhale S, Singh HP, Kandwal A. Evaluation of platelet-rich plasma alone or in combination with demineralized freeze dried bone allograft in treatment of periodontal infrabony defects: A comparative clinical trial. *J Indian Soc Periodontol*. 2016 Jan-Feb;20(1):42-7. doi: 10.4103/0972-124X.170811.
6. Jethwa J, Ireland RS, Chan D. Does a combination of platelet-rich plasma and decalcified freeze-dried bone allograft offer advantages over decalcified freeze-dried bone allograft alone when using pocket depth and clinical attachment level as markers for periodontal healing? A literature review. *J Investig Clin Dent*. 2019 May;10(2):e12397. doi: 10.1111/jicd.12397.
7. Dohan DM, Choukroun J, Diss A, Dohan SL, Dohan AJ, Mouhyi J, et al. Platelet-rich fibrin (PRF): a second-generation platelet concentrate. Part II: platelet-related biologic features. *Oral Surg Oral Med Oral Pathol Oral Radiol Endod*. 2006 Mar;101(3):e45-50. doi: 10.1016/j.tripleo.2005.07.009.
8. Pradeep AR, Bajaj P, Rao NS, Agarwal E, Naik SB. Platelet-rich fibrin combined with a porous hydroxyapatite graft for the treatment of 3-wall intrabony defects in chronic periodontitis: a randomized controlled clinical trial. *J Periodontol*. 2017 Dec;88(12):1288-96. doi: 10.1902/jop.2012.110722.
9. Miron RJ, Fujioka-Kobayashi M, Hernandez M, Kandalam U, Zhang Y, Ghanaati S, et al. Injectable platelet rich fibrin (i-PRF): opportunities in regenerative dentistry? *Clin Oral Investig*. 2017 Nov;21(8):2619-27. doi: 10.1007/s00784-017-2063-9.
10. Shanellec DA. Periodontal microsurgery. *J Esthet Restor Dent*. 2003;15(7):402-7; discussion 408. doi: 10.1111/j.1708-8240.2003.tb00965.x.
11. Cortellini P, Tonetti MS. Microsurgical approach to periodontal regeneration. Initial evaluation in a case cohort. *J Periodontol*. 2001 Apr;72(4):559-69. doi: 10.1902/jop.2001.72.4.559.
12. Jain R, Kudva P, Kumar R, Nagar S. Periodontal microsurgery-magnifying facts, maximizing results. *J Adv Med Dent Sci Res*. 2014;2(3):24-34.

13. Silness J, Loe H. Periodontal disease in pregnancy. II. Correlation between oral hygiene and periodontal condition. *Acta Odontol Scand*. 1964 Feb;22:121-35. doi: 10.3109/00016356408993968.
14. Mombelli A, van Oosten MA, Schurch E Jr, Land NP. The microbiota associated with successful or failing osseointegrated titanium implants. *Oral Microbiol Immunol*. 1987 Dec;2(4):145-51. doi: 10.1111/j.1399-302x.1987.tb00298.x.
15. Mourão CF, Valiense H, Melo ER, Mourão NB, Maia MD. Obtention of injectable platelets rich-fibrin (i-PRF) and its polymerization with bone graft: technical note. *Rev Col Bras Cir*. 2015 Nov-Dec;42(6):421-3. doi: 10.1590/0100-69912015006013.
16. Sculean A, Nikolidakis D, Nikou G, Ivanovic A, Chapple IL, Stavropoulos A. Biomaterials for promoting periodontal regeneration in human intrabony defects: a systematic review. *Periodontol* 2000. 2015 Jun;68(1):182-216. doi: 10.1111/prd.12086.
17. Bowers G, Felton F, Middleton C, Glynn D, Sharp S, Mellonig J, et al. Histologic comparison of regeneration in human intrabony defects when osteogenin is combined with demineralized freeze-dried bone allograft and with purified bovine collagen. *J Periodontol*. 1991 Nov;62(11):690-702. doi: 10.1902/jop.1991.62.11.690.
18. Najeeb S, Khurshid Z, Agwan MAS, Ansari SA, Zafar MS, Matinlinna JP. Regenerative Potential of Platelet Rich Fibrin (PRF) for curing intrabony periodontal defects: a systematic review of clinical studies. *Tissue Eng Regen Med*. 2017 Sep;14(6):735-42. doi: 10.1007/s13770-017-0079-5.
19. Shah R, Gowda TM, Thomas R, Kumar T, Mehta DS. Biological activation of bone grafts using injectable platelet-rich fibrin. *J Prosthet Dent*. 2019 Mar;121(3):391-3. doi: 10.1016/j.prosdent.2018.03.027.
20. Elgendy EA, Abo Shady TE. Clinical and radiographic evaluation of nanocrystalline hydroxyapatite with or without platelet-rich fibrin membrane in the treatment of periodontal intrabony defects. *J Indian Soc Periodontol*. 2015 Jan-Feb;19(1):61-5. doi: 10.4103/0972-124X.148639.
21. Wang X, Zhang Y, Choukroun J, Ghanaati S, Miron RJ. Effects of an injectable platelet-rich fibrin on osteoblast behavior and bone tissue formation in comparison to platelet-rich plasma. *Platelets*. 2018 Jan;29(1):48-55. doi: 10.1080/09537104.2017.1293807.
22. Sharma A, Pradeep AR. Treatment of 3-wall intrabony defects in patients with chronic periodontitis with autologous platelet-rich fibrin: a randomized controlled clinical trial. *J Periodontol*. 2011 Dec;82(12):1705-12. doi: 10.1902/jop.2011.110075.
23. Zhang J, Yin C, Zhao Q, Zhao Z, Wang J, Miron RJ, et al. Anti-inflammation effects of injectable platelet-rich fibrin via macrophages and dendritic cells. *J Biomed Mater Res A*. 2020 Jan;108(1):61-8. doi: 10.1002/jbm.a.36792.
24. Khosropanah H, Shahidi S, Basri A, Houshyar M. Treatment of intrabony defects by DFDBA alone or in combination with PRP: a split-mouth randomized clinical and three-dimensional radiographic trial. *J Dent (Tehran)*. 2015 Oct;12(10):764-73.
25. Caton JG, Greenstein G. Factors related to periodontal regeneration. *Periodontol* 2000. 1993 Feb;1(1):9-15.
26. Kao RT, Nares S, Reynolds MA. Periodontal regeneration - intrabony defects: a systematic review from the AAP Regeneration Workshop. *J Periodontol*. 2015 Feb;86(2 Suppl):S77-104. doi: 10.1902/jop.2015.130685.
27. Wachtel H, Schenk G, Böhm S, Weng D, Zuhr O, Hürzeler MB. Microsurgical access flap and enamel matrix derivative for the treatment of periodontal intrabony defects: a controlled clinical study. *J Clin Periodontol*. 2003 Jun;30(6):496-504. doi: 10.1034/j.1600-051x.2003.00013.x.