








# Influence of different working lengths on the shaping ability of Reciproc Blue in the apical third and apical foramen: a micro-computed tomographic study

Rafael Henrique de Oliveira Carvalho<sup>1</sup> , Marcelo Santos Coelho<sup>1</sup> , Hugo Victor Dantas<sup>2</sup> , Frederico Barbosa de Sousa<sup>3</sup> , Aline Cristine Gomes Matta<sup>4\*</sup> , Adriana de Jesus Soares<sup>4</sup> , Marcos Roberto dos Santos Frozoni<sup>1</sup> 

<sup>1</sup> Department of Endodontics, São Leopoldo Mandic Research Center, Campinas, São Paulo, Brazil.

<sup>2</sup> Department of Restorative Dentistry, Health Sciences Center, Federal University of Paraíba, Joao Pessoa, Paraíba, Brazil.

<sup>3</sup> Department of Morphology, Health Sciences Center, Federal University of Paraíba, João Pessoa, Paraíba, Brazil.

<sup>4</sup> Department of Restorative Dentistry, Endodontics Area, Piracicaba Dental School, University of Campinas, Piracicaba, São Paulo, Brazil.

## Corresponding author:

Aline Cristine Gomes Matta  
Faculdade de Odontologia de  
Piracicaba - UNICAMP  
Avenida Limeira, 901 -  
CEP: 13.414-903 – Piracicaba,  
SP, Brazil  
E-mail: linecristine@msn.com

**Editor:** Dr. Altair A. Del Bel Cury

**Received:** November 11, 2022

**Accepted:** February 2, 2023

**Aim:** This study aimed to assess the shaping ability of Reciproc Blue in the apical third and apical foramen of moderately curved canals at different working lengths (WLs), by micro-computed tomography. **Methods:** Thirty-six mesial roots (mesiobuccal and mesiolingual canals) were included, each with 2 separate root canals and independent apical foramina, according to type IV of Vertucci's classification of first and second mandibular molars. The canals were instrumented at three different WLs: G-1, 1mm short of the major apical foramen; G0, at the major apical foramen; G+1, 1mm beyond the major apical foramen. The groups were assessed for changes in root canal volume and untouched wall area in the apical third. Groups G0 and G+1 were also compared for percentage of untouched walls at the apical foramen. One-way ANOVA (post hoc Tukey test) and Student's t-test adopted a 5% level of significance. **Results:** Root canal volumes (mm<sup>3</sup>) in the apical third were 22.86±10.46, 44.48±24.91, and 55.71±21.32 in G-1, G0 and G+1, respectively. G-1 volume following instrumentation increased significantly less than that of G0 or G+1 (P>.05); G0 did not differ from G+1. The percentage of untouched wall area in the apical third did not differ among the three groups (P>.05). G0 and G+1 did not differ regarding untouched walls in the major apical foramen walls. **Conclusion:** Extending the WL from 1mm short of the apical foramen to a point at and beyond the WL increases the apical third volume without increasing the prepared area. Untouched surface areas of the apical foramen were not modified by instrumentation at or beyond the foramen.

**Keywords:** Tooth apex. Dental pulp cavity. Periapical periodontitis. Root canal therapy. X-Ray microtomography.



## Introduction

Root canal preparation requires an instrument that can touch the root canal walls to remove the infected dentin and biofilm<sup>1</sup>. This step uses irrigation as an essential adjunct to remove microorganisms and their by-products from the root canal system. The current status of root canal instrumentation is unable to fully prepare the root canal walls. Despite the constant development of new instruments with different cross-sections, alloys and kinematics, many root canal walls remain untouched<sup>2</sup>. Accordingly, complete disinfection of the root canal system has yet to be achieved.

This drawback is of greater importance in the apical third, because preparation leaves a larger number of untouched dentin walls, responsible for harboring remnants of pulp tissue and bacteria<sup>3</sup>. Apical biofilm is found in up to 80% of the teeth with apical periodontitis<sup>4</sup>. Histological studies have shown the presence of microorganisms in the cemental canal and foraminal areas<sup>5-7</sup>. Foraminal enlargement has been proposed by some authors<sup>8,9</sup> to enhance the mechanical-chemical preparation of these critical apical regions, so that cemental canal contamination can be better cleaned. In addition, Khademi et al.<sup>10</sup> demonstrated that a minimum instrumentation size of 30 is needed for efficient penetration of irrigants in the apical third. This objective may be achieved by performing a larger apical preparation that can reach the major apical foramen in order to enhance disinfection of this critical area<sup>11</sup>. A larger preparation decreases the bacterial load by removing infected dentin while improving irrigation<sup>12</sup>. Although this procedure might traumatize periodontal tissues and thus increase postoperative pain, recent studies have reported controversial results for foraminal enlargement<sup>13</sup>. Another controversial topic is possible foraminal deformation. A previous study showed that foraminal enlargement with both rotary and reciprocating instruments promotes foraminal deformation if the canal is not sealed properly<sup>14</sup>.

Using an electronic apex locator (EAL) to determine the working length (WL) is well established in the literature<sup>15</sup>. However, the measurements provided by the EAL can vary from -0.5 to +0.5 mm of the major apical foramen<sup>15</sup>. Variations in WL measurement can affect the extent of the preparation of the apical foramen and may cause foraminal overinstrumentation. Accordingly, inadvertent instrumentation beyond the major apical foramen can occur during apical third modeling, and could exacerbate the inflammatory process, increase postoperative pain, and compromise apical healing and repair<sup>16,17</sup>.

The current development of new alloys has rendered instruments more flexible and resistant to cyclic and torsional fatigue<sup>18</sup>. The Reciproc Blue system (VDW, Munich, Germany) is one of these new instruments that uses a heat-treated alloy<sup>19</sup>. The heating and cooling during fabrication of the Reciproc Blue system promote the deposition of titanium oxide, resulting in a bluish color. These files also have an S-shaped cross-section and an inactive tip<sup>20</sup>. So far, little is known about the influence of this new alloy on the features of the apical third and major apical foramen after root canal shaping.

Several methods have been developed to evaluate the shaping ability of endodontic instrumentation systems. Micro-computed tomography (micro-CT) is considered the gold standard for this purpose, since it allows highly accurate, three-dimensional, and noninvasive assessment of the root canal system<sup>21</sup>. Therefore, this study used micro-CT to evaluate the root canal shaping ability, the changes in root canal volume, and the untouched wall area in the apical third and the major apical foramen of curved canals prepared at different WLs. To this end, two null hypotheses were tested. The first posits that the increase in volume and the touching of walls in the apical third is the same for the 3 groups. The second presumes that the number of untouched walls in the foraminal area is the same for G0 and G+1.

## Materials and Methods

This ex vivo study was approved by the Ethics Committee of the São Leopoldo Mandic School of Dentistry (#4.019.306). The sample size was calculated based on a previous study<sup>22</sup>, considering a test power of 80% and a significance level of 5%, and resulted in 11 specimens per group. Thus, 36 human specimens (n = 12 per group) were selected for the present study.

### Sample selection

This study included mesial roots of first and second mandibular molars with 2 separate root canals and independent apical foramina, according to type IV of Vertucci's classification, extracted for reasons not related to the study. The specimens were kept in distilled water at 4°C throughout the experiment. The roots were examined under a dental operating microscope (Zeiss PICO, Jena, Germany) at 16x magnification to exclude those with signs of cracks or fractures. The distal roots and crowns were then removed, and the remaining 18 mm of the roots were radiographed in the buccolingual and mesiodistal directions to select roots with moderate curvature (10° to 20°), following Schneider's method<sup>23</sup>. The assessment excluded roots with internal or external resorptions or pulp canal obliteration observed by radiography, roots with incomplete apex formation, teeth with previous endodontic treatment, extensive root caries, cracks or fractures observed in an OPMI PICO microscope (Carl Zeiss, Jena, Germany) at 10x magnification, obliterations, calcifications, and roots with foraminal diameter greater than a size 15 manual K-file (Dentsply Sirona Endodontia). In addition, a size 15.02 file (Dentsply Sirona, Ballaigues, Switzerland) was used to determine whether the foraminal diameter met the inclusion criteria, i.e., no larger than #15.

### Acquisition of pre-instrumentation micro-CT images

Prior to instrumentation, the specimens were scanned by a micro-CT device (SkyScan 1172; Bruker microCT, Kontich, Belgium) using the following parameters: 100 kV, 100 mA, 24.9- $\mu$ m resolution, rotation step of 0.6° over 180° rotation, frame average of 4, and 30 minutes of exposure. Copper and aluminum filters were applied. After scanning, the images were reconstructed and converted to bitmap format with NRecon software (NRecon version 1.5.23, Bruker microCT), resulting in 600 to 700 images per specimen. A #5 smoothing filter, a ring artefact reduction of 5, and a 30%

beam hardening correction were used for reconstruction. The samples were then randomly divided into three experimental groups (n = 12 each).

### **Alveolar bone and periodontal ligament simulation**

Alveolus simulation was achieved by wrapping the roots in a thin layer of aluminum and inserting them into self-curing acrylic resin (Duralay Dental, Worth, IL, USA) until setting. The roots were then removed from the tube, the aluminum was discarded, and the impression material (Express XT, Neuss, Germany) was placed inside the simulated alveolus. Lastly, the roots were gently placed inside the acrylic tube, with the thin layer of impression material mimicking the periodontal ligament<sup>24</sup>.

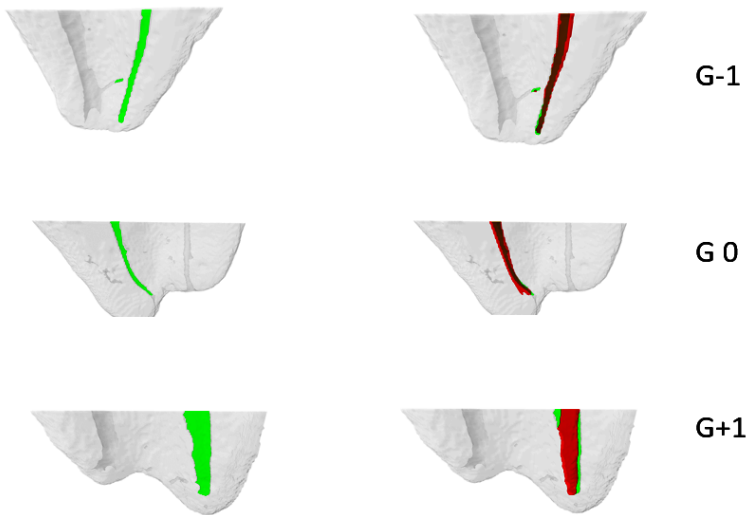
### **Root canal instrumentation**

The specimens were randomly divided into the experimental groups according to the established WL, based on a size 10 K-file visible at the major apical foramen at 16x magnification. In G-1 (n = 12), instrumentation was performed 1 mm short of the major apical foramen; in G0 (n = 12), at the major apical foramen, and in G+1 (n = 12), 1 mm beyond the major apical foramen.

All instrumentation procedures were performed with Reciproc Blue R25 files (VDW, Munich, Germany) powered by a VDW Silver (VDW) motor and using the "RECIP-ROC ALL" setting. The instrument was placed at the entrance of the canal, and three in-and-out movements were made with an amplitude of approximately 3-4 mm. The instrument was removed and cleaned with alcohol-soaked gauze after each set of movements. The canal was irrigated with 5 mL of 2.5% NaOCl, and patency was confirmed with a size 15 K-file 1 mm beyond the apex. Irrigation was performed 3 mm from the major apical foramen with a size 30 needle (Ultradent, South Jordan, UT) connected to a disposable syringe. The syringe was coupled to a peristaltic pump (LAP-101-3; MS TCNOPON, Piracicaba, SP, Brazil) to ensure the same total irrigation volume (15 mL) and flow rate (5 mL/minute) in each canal. These movements were carried out until the WL was reached. After the instrumentation was concluded, the canal was irrigated with 5 mL of 17% EDTA, followed by 5 mL of 0.9% saline. The canal was then dried with capillary tips (Ultradent, South Jordan, UT) and paper points.

### **Evaluation of pre- and post-instrumentation micro-CT images**

After instrumentation of the three experimental groups, a second micro-CT scan and tomographic image reconstruction were performed following the same protocol as that used for the initial scan. The specimens served as their own controls in the assessments. The 3D registration function of DataView software (Bruker MicroCT) was used to superimpose the pre- and post-instrumentation images, and CT-Analyzer v.1.13 (Bruker) was used to calculate quantitative parameters and construct visual 3D models from the recorded images. A qualitative comparison among the groups was performed using color-coded models of the corresponding root canals, where green and red indicated pre- and postoperative surfaces of the canal, respectively (Figure 1). CTVol v.2.0 software (Bruker microCT) was used for this analysis.



**Figure 1.** Images of the samples instrumented in mesiobuccal and mesiolingual canals. Preoperative (green) and superimposed (red) features of the canals in each group are shown.

The volume of interest in each sample extended from the foramen to 4 mm in the cervical direction of the mesial root. It was established by integrating the regions of interest over all the cross-sections. The ash scale needed to recognize the dentin before and after instrumentation was determined based on histogram density using the global limit method.

The mean percentage increase ( $\Delta\%$ ) in volume and surface area was calculated using the following formula:  $([Pa - Pb]/Pb) * 100$ , where Pb and Pa represented the values of the parameters evaluated before and after preparation, respectively. The percentage of the remaining untouched surface area was calculated as  $(Au/Ab) * 100$ , where Au was the untouched canal wall area, and Ab was the root canal wall area before preparation<sup>25</sup>.

The Kolmogorov-Smirnov test showed normal distribution of the data. Thus, one-way ANOVA (post hoc Tukey test) was performed to assess the volume increase and amount of untouched areas in the apical third. The Student's t-test was performed to evaluate the untouched areas in the major apical foramen, by comparing the data among the groups. The Statistical Package for Social Sciences (SPSS, version 19) was used for analysis, adopting a 5% level of significance.

## Results

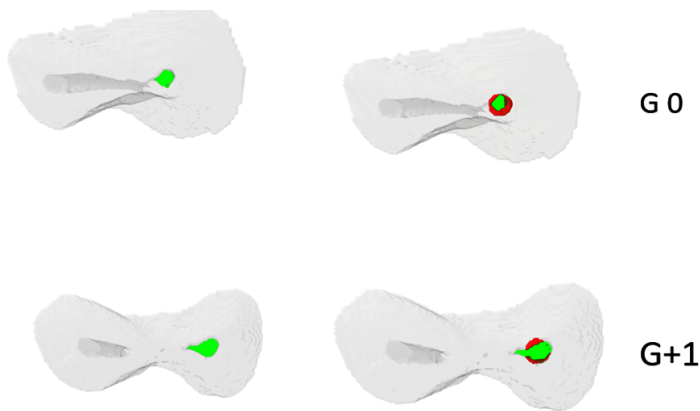
The radiographic measurements showed similar curvature and length parameters of the sample (data not shown). Micro-CT analyses revealed similar baseline volume ( $\text{mm}^3$ ) and area ( $\text{mm}^2$ ) of dentin in the apical third of the samples in G-1, G0 and G+1. Moreover, the major apical foramen areas were similar in G0 and G+1 (Table 1).

**Table 1.** Mean (SD) baseline volume and dentin area in the apical third of samples in G-1, G0 and G+1, and mean baseline apical foramen area in G0 and G+1.

Group	Baseline volume (mm <sup>3</sup> )	Baseline dentin area (mm <sup>2</sup> )	Baseline apical foramen area (mm <sup>2</sup> )
G-1	0.56 (0.34)	30.13 (8.62)	--
G0	0.51 (0.42)	29.61 (5.89)	0.86 (0.40)
G+1	0.50 (0.33)	30.03 (4.00)	1.13 (0.24)
p-value	0.924	0.981	0.055

One-way ANOVA (post hoc Tukey test) indicated no significant difference at  $P < .05$  for volume or dentin area in the apical third, or for the apical foramen area.

Representative baseline and post-instrumentation images of the apical third in the three experimental groups are depicted in Figure 1. Figure 2 shows representative baseline and post-instrumentation images of the foramen in G0 and G+1. In Table 2. For group G-1, the touch of walls in the major apical foramen was not analyzed, because in this group there was no foraminal preparation. No significant differences in untouched wall areas at the major apical foramen were observed between G0 and G+1 ( $P > .05$ ) (Table 2).

**Figure 2.** Representative images of the superimposed features of the major apical foramen in G0 and G+1**Table 2.** Mean (SD) percentage of untouched wall area at the apical foramen in the two groups

Group	Untouched wall at the foramen (%)
G0	20.13 ( $\pm 13.33$ )
G+1	13.87 ( $\pm 6.96$ )
p-value	0.163

Student's t-test indicates no significant differences at  $P > .05$

The increase in root canal volume in the apical third was significantly smaller in G-1 compared to G0 and G+1 ( $P < .05$ ), which were similar (Table 3). The percentage of untouched wall areas in the apical third was similar among the groups ( $P > .05$ ) (Table 3).

**Table 3.** Mean (SD) percentage increase in root canal volume and amount of untouched wall area in the apical third in the three groups.

Group	Increase in apical third volume (%)	Untouched area in the apical third (%)
G-1	22.86 ( $\pm 10.46$ ) <sup>a</sup>	20.33 ( $\pm 4.90$ ) <sup>a</sup>
G0	44.48 ( $\pm 24.91$ ) <sup>b</sup>	21.23 ( $\pm 6.10$ ) <sup>a</sup>
G+1	55.71 ( $\pm 21.32$ ) <sup>b</sup>	21.29 ( $\pm 5.80$ ) <sup>a</sup>
p-value	0.001	0.896

## Discussion

For many years, the WL was established as being 1 mm short of the apical terminus, because authors believed that this was the ideal point to decrease apical zip and perforations, and to maintain the connective tissue in the apical region. However, most accessory root canals and foramina are located in the final millimeter of the root canal<sup>22</sup>, and biofilm and bacteria can colonize the cementum root canal in necrotic teeth. In view of this complexity, some authors recommend instrumentation beyond the area of constriction, currently considered as an acceptable end point of root canal instrumentation<sup>23</sup>. In the present study, root canal instrumentation was performed on teeth 1 mm short of the major apical foramen (G-1), and at the major apical foramen (G0), noting that both locations mimic clinical situations.

Strict selection criteria were applied to minimize sample variations. First, the teeth were evaluated by two-dimensional radiography. The length of the specimens was standardized, and the curvature angles were calculated with the image software. Subsequently, the specimens were scanned by micro-CT, which is currently the most accepted method for evaluating root canal morphology. The random distribution of the specimens established similar three-dimensional characteristics among the groups, thus minimizing the possible drawback of having different sized samples<sup>26</sup>.

The present study aimed to assess whether different WLs increase the root canal volume and decrease the untouched wall area in the apical third. The results showed that instrumentation 1 mm short of the foramen resulted in a smaller increase in apical third volume. This suggests that instrumentation at the foramen or beyond is more likely to increase the root canal volume in the apical third, compared to instrumentation 1 mm short of the apex, when using reciprocating NiTi system. For the volume of the apical third the first null hypothesis was rejected. A smaller volume can reduce the space for irrigating solutions<sup>27</sup>. Boutsikaris et al.<sup>28</sup> (2010) demonstrated that apical preparation size affects irrigant replacement, shear stress on the canal wall, and pressure at the major apical foramen.

The current reach of root canal instrumentation is unable to fully clean all root canal walls<sup>29</sup>, whereas the ultimate instrumentation goal is to touch as many walls as possi-

ble, to remove infected dentin and biofilm<sup>23</sup>. The apical third of the root canal is considered the most critical area for complete disinfection and removal of necrotic content<sup>30</sup>. However, in the present study, the different WLs did not affect the untouched wall area in the apical third (Table 3). Therefore, according to the wall-touching analysis for the apical third, the first null hypothesis was accepted.

As for the apical foramen instrumentation, the WL at or beyond the foramen provided the same outcome in terms of increased instrumentation in the foramen area and amount of untouched walls at the foramen. Therefore, the second null hypothesis was accepted. The measurements provided by the EAL oscillated between -0.5 and +0.5 mm from the major apical foramen<sup>31</sup>. This result suggests that instrumentation beyond the apical foramen may be undesirable. This study showed that extending the WL 1 mm beyond the foramen does not decrease untouched walls in either the apical third or the major apical foramen and has no advantage when compared to preparation at the foramen.

A previous study by scanning electronic microscopy demonstrated that instrumentation at the foramen or 1 mm beyond it promoted foraminal deformation with both reciprocating and rotary kinematics<sup>32</sup>. Another study confirmed this finding, but showed that this deformation does not affect the outcome of the root canal filling<sup>9</sup>. However, the findings of these studies were obtained by root canal instrumentation with rotary or reciprocating instruments using either NiTi or M-Wire alloys. Although the overall preparation of the canal seems to be unaffected by the new M-wire alloy<sup>33</sup>, the files made with this alloy seem to better preserve the anatomical features of the foramen when foraminal enlargement is performed in a straight or moderately curved canal<sup>34</sup>. Considering the optimal performance of these files in lessening foraminal deformation, better results for decreasing the percentage of untouched dentin would be expected. This is of great importance in endodontics, since untouched walls can result in the failure of root canal treatment<sup>3</sup>.

The present results showed 20.33% of untouched root canal walls after preparation 1 mm short of the major apical foramen, similar to the 22.9% obtained by Pérez et al.<sup>35</sup> for the same root canal walls. Our results suggest that preparation short of the major apical foramen touches the same percentage of dentin walls as the preparation at or beyond the major apical foramen (21.23% and 21.29% respectively). In the present study, an increase in the apical third volume was observed when the WL was determined at the foramen or 1 mm beyond it. However, the increase in canal volume did not result in a decrease in untouched root canal walls, but did improve the action of irrigation solutions in this region.

A recent study compared the WaveOne instrument—also a reciprocating 25.08 instrument—with two different rotary instruments regarding changes in canal volume and untouched area and found no difference among the instruments<sup>36</sup>. The findings of the present study are similar to those reported by Coelho et al.<sup>36</sup>, who asserted that the WaveOne instrument promoted a greater increase in root canal volume than Easy Prodesign Logic (Easy Endodontics, Belo Horizonte, Brazil) and One Shape (Micro Mega, Besançon, France). However, this volume increase did not result in a reduction in untouched areas in the apical third.



Fornari et al.<sup>37</sup> demonstrated that enlargement of the apical third up to size 40.02 or 45.02 resulted in fewer untouched walls than a preparation up to size 30.02 or 35.02. Similar findings have been reported by De-Deus et al.<sup>38</sup>, who found that the percentage of untouched walls significantly decreased by enlarging the file sizes from #25 to #40 of the Reciproc, WaveOne and Biorace instruments. In the present study, a 25.08 file went 1 mm through the foramen, resulting in a preparation size of 33 at the major apical foramen; interestingly, this did not decrease the number of untouched walls in the apical third. It can be concluded that considerable apical enlargement is required to reduce the untouched area in the apical third of root canals, and that instrumentation beyond the foramen does not seem to affect this outcome.

Although there was a smaller increase in the apical third volume with instrumentation 1 mm short of the foramen, the percentage of untouched area in the apical third in the G-1 group was similar to that of the other groups. This is because root canal irregularities like isthmuses and fins were not reached by the root canal preparation even at the different WLs.

The results of the present study must be analyzed with caution because of the *ex vivo* model adopted. Future studies should assess the impact of larger instruments on increasing the root canal volume and decreasing the untouched areas using heat-treated files.

In conclusion, the preparation at or beyond the major apical foramen increases the root canal volume in the apical third and does not affect the percentage of untouched walls in the apical third or at the apical foramen.

## Conflict of Interest

All of the authors declare that there is no conflict of interest.

## Funding

This study had no funding.

## Ethical approval

This article does not contain any studies with human participants or animals performed by any of the authors.

## Informed consent

Formal consent is not required for this type of study.

## Author contribution

**Rafael Henrique de Oliveira Carvalho:** Methodology, Research, Image Evaluation, Data Organization, Writing.

**Marcelo Santos Coelho:** Formal Analysis, Writing, Review and Editing.

**Hugo Victor Dantas:** Formal Data Analysis, Initial Writing, Review and Editing.

**Frederico Barbosa de Sousa:** Formal Data Analysis, Initial Writing, Review and Editing.

**Aline Cristine Gomes Matta:** Formal Analysis, Writing, Review and Editing.

**Adriana de Jesus Soares:** Conceptualization, Methodology, Supervision, Project Management.

**Marcos Roberto dos Santos Frozoni:** Conceptualization, Methodology, Supervision, Project Management.

All authors actively participated in the manuscript's findings, revised, and approved the final version of the manuscript.

---

## References

1. Peters OA. Current challenges and concepts in the preparation of root canal systems: a review. *J Endod.* 2004 Aug;30(8):559-67. doi: 10.1097/01.don.0000129039.59003.9d.
2. Zuolo ML, Zaia AA, Belladonna FG, Silva EJNL, Souza EM, Versiani MA, et al. Micro-CT assessment of the shaping ability of four root canal instrumentation systems in oval-shaped canals. *Int Endod J.* 2018 May;51(5):564-71. doi: 10.1111/iej.12810.
3. Siqueira JF Jr, Pérez AR, Marceliano-Alves MF, Provenzano JC, Silva SG, Pires FR, et al. What happens to unprepared root canal walls: a correlative analysis using micro-computed tomography and histology/scanning electron microscopy. *Int Endod J.* 2018 May;51(5):501-8. doi: 10.1111/iej.12753.
4. Ricucci D, Siqueira JF Jr. Biofilms and apical periodontitis: study of prevalence and association with clinical and histopathologic findings. *J Endod.* 2010 Aug;36(8):1277-88. doi: 10.1016/j.joen.2010.04.007.
5. Nair PN. On the causes of persistent apical periodontitis: a review. *Int Endod J.* 2006 Apr;39(4):249-81. doi: 10.1111/j.1365-2591.2006.01099.x.
6. Ribeiro FC, Consolaro A, Pinheiro TN. Bacterial distribution in teeth with pulp necrosis and apical granuloma. *Int J Experiment Dent Sci.* 2013;2(2):86-91. doi: 10.5005/jp-journals-10029-1047.
7. Signoretti FG, Endo MS, Gomes BP, Montagner F, Tosello FB, Jacinto RC. Persistent extraradicular infection in root-filled asymptomatic human tooth: scanning electron microscopic analysis and microbial investigation after apical microsurgery. *J Endod.* 2011 Dec;37(12):1696-700. doi: 10.1016/j.joen.2011.09.018.
8. Brandão PM, de Figueiredo JAP, Morgental RD, Scarparo RK, Hartmann RC, Waltrick SBG, et al. Correction to: Influence of foraminal enlargement on the healing of periapical lesions in rat molars. *Clin Oral Investig.* 2019 Apr;23(4):2001-3. doi: 10.1007/s00784-018-2780-8. Erratum for: *Clin Oral Investig.* 2019 Apr;23(4):1985-91.
9. Silva JM, Brandão GA, Silva EJ, Zaia AA. Influence of working length and foraminal enlargement on foramen morphology and sealing ability. *Indian J Dent Res.* 2016 Jan-Feb;27(1):66-72. doi: 10.4103/0970-9290.179834.
10. Khademi A, Yazdizadeh M, Feizianfard M. Determination of the minimum instrumentation size for penetration of irrigants to the apical third of root canal systems. *J Endod.* 2006 May;32(5):417-20. doi: 10.1016/j.joen.2005.11.008.
11. Saini HR, Tewari S, Sangwan P, Duhan J, Gupta A. Effect of different apical preparation sizes on outcome of primary endodontic treatment: a randomized controlled trial. *J Endod.* 2012 Oct;38(10):1309-15. doi: 10.1016/j.joen.2012.06.024.

12. Pérez AR, Alves FRF, Marceliano-Alves MF, Provenzano JC, Gonçalves LS, Neves AA, Siqueira JF Jr. Effects of increased apical enlargement on the amount of unprepared areas and coronal dentine removal: a micro-computed tomography study. *Int Endod J*. 2018 Jun;51(6):684-90. doi: 10.1111/iej.12873.
13. Silva EJ, Menaged K, Ajuz N, Monteiro MR, Coutinho-Filho TS. Postoperative pain after foraminal enlargement in anterior teeth with necrosis and apical periodontitis: a prospective and randomized clinical trial. *J Endod*. 2013 Feb;39(2):173-6. doi: 10.1016/j.joen.2012.11.013.
14. Silva JM, Brandão GA, Silva EJ, Zaia AA. Influence of working length and foraminal enlargement on foramen morphology and sealing ability. *Indian J Dent Res*. 2016 Jan-Feb;27(1):66-72. doi: 10.4103/0970-9290.179834.
15. Stoll R, Urban-Klein B, Roggendorf MJ, Jablonski-Momeni A, Strauch K, Frankenberger R. Effectiveness of four electronic apex locators to determine distance from the apical foramen. *Int Endod J*. 2010 Sep;43(9):808-17. doi: 10.1111/j.1365-2591.2010.01765.x.
16. Silva EJ, Menaged K, Ajuz N, Monteiro MR, Coutinho-Filho TS. Postoperative pain after foraminal enlargement in anterior teeth with necrosis and apical periodontitis: a prospective and randomized clinical trial. *J Endod*. 2013 Feb;39(2):173-6. doi: 10.1016/j.joen.2012.11.013.
17. Saini HR, Sangwan P, Sangwan A. Pain following foraminal enlargement in mandibular molars with necrosis and apical periodontitis: A randomized controlled trial. *Int Endod J*. 2016 Dec;49(12):1116-23. doi: 10.1111/iej.12583.
18. Keskin C, Inan U, Demiral M, Keleş A. Cyclic fatigue resistance of reciproc blue, reciproc, and waveone gold reciprocating instruments. *J Endod*. 2017 Aug;43(8):1360-3. doi: 10.1016/j.joen.2017.03.036.
19. De-Deus G, Silva EJ, Vieira VT, Belladonna FG, Elias CN, Plotino G, et al. Blue thermomechanical treatment optimizes fatigue resistance and flexibility of the reciproc files. *J Endod*. 2017 Mar;43(3):462-6. doi: 10.1016/j.joen.2016.10.039.
20. Gündoğar M, Özyürek T. Cyclic fatigue resistance of oneshape, hyflex edm, waveone gold, and reciproc blue nickel-titanium instruments. *J Endod*. 2017 Jul;43(7):1192-6. doi: 10.1016/j.joen.2017.03.009.
21. Peters OA, Laib A, Göhring TN, Barbakow F. Changes in root canal geometry after preparation assessed by high-resolution computed tomography. *J Endod*. 2001 Jan;27(1):1-6. doi: 10.1097/00004770-200101000-00001.
22. Kim S, Kratchman S. Modern endodontic surgery concepts and practice: a review. *J Endod*. 2006 Jul;32(7):601-23. doi: 10.1016/j.joen.2005.12.010.
23. Ricucci D, Langeland K. Apical limit of root canal instrumentation and obturation, part 2. A histological study. *Int Endod J*. 1998 Nov;31(6):394-409. doi: 10.1046/j.1365-2591.1998.00183.x.
24. Pitts DL, Matheny HE, Nicholls JI. An in vitro study of spreader loads required to cause vertical root fracture during lateral condensation. *J Endod*. 1983 Dec;9(12):544-50. doi: 10.1016/S0099-2399(83)80058-2.
25. Markvart M, Darvann TA, Larsen P, Dalstra M, Kreiborg S, Bjørndal L. Micro-CT analyses of apical enlargement and molar root canal complexity. *Int Endod J*. 2012 Mar;45(3):273-81. doi: 10.1111/j.1365-2591.2011.01972.x.
26. De-Deus G, Simões-Carvalho M, Belladonna FG, Versiani MA, Silva EJNL, Cavalcante DM, et al. Creation of well-balanced experimental groups for comparative endodontic laboratory studies: a new proposal based on micro-CT and in silico methods. *Int Endod J*. 2020 Jul;53(7):974-85. doi: 10.1111/iej.13288.
27. Srikanth P, Krishna AG, Srinivas S, Reddy ES, Battu S, Aravelli S. Minimal apical enlargement for penetration of irrigants to the apical third of root canal system: a scanning electron microscope study. *J Int Oral Health*. 2015 Jun;7(6):92-6.

28. Boutsoukias C, Gogos C, Verhaagen B, Versluis M, Kastrinakis E, Van der Sluis LW. The effect of apical preparation size on irrigant flow in root canals evaluated using an unsteady Computational Fluid Dynamics model. *Int Endod J*. 2010 Oct;43(10):874-81. doi: 10.1111/j.1365-2591.2010.01761.x.
29. Paqué F, Ganahl D, Peters OA. Effects of root canal preparation on apical geometry assessed by micro-computed tomography. *J Endod*. 2009 Jul;35(7):1056-9. doi: 10.1016/j.joen.2009.04.020.
30. Siqueira JF Jr, Rôças IN, Provenzano JC, Guilherme BP. Polymorphism of the FcγRIIIa gene and post-treatment apical periodontitis. *J Endod*. 2011 Oct;37(10):1345-8. doi: 10.1016/j.joen.2011.06.025.
31. Piasecki L, José Dos Reis P, Jussiani EI, Andreello AC. A micro-computed tomographic evaluation of the accuracy of 3 electronic apex locators in curved canals of mandibular molars. *J Endod*. 2018 Dec;44(12):1872-7. doi: 10.1016/j.joen.2018.09.001.
32. Silva Santos AM, Portela FMSF, Coelho MS, Fontana CE, De Martin AS. Foraminal deformation after foraminal enlargement with rotary and reciprocating kinematics: a scanning electronic microscopy study. *J Endod*. 2018 Jan;44(1):145-8. doi: 10.1016/j.joen.2017.08.013.
33. Belladonna FG, Carvalho MS, Cavalcante DM, Fernandes JT, de Carvalho Maciel AC, et al. Micro-computed tomography shaping ability assessment of the new blue thermal treated reciproc instrument. *J Endod*. 2018 Jul;44(7):1146-50. doi: 10.1016/j.joen.2018.03.008.
34. Daou C, El Hachem R, Naaman A, Zogheib C, El Osta N, Khalil I. Effect of 2 heat-treated nickel-titanium files on enlargement and deformation of the apical foramen in curved canals: a scanning electronic microscopic study. *J Endod*. 2020 Oct;46(10):1478-84. doi: 10.1016/j.joen.2020.07.019.
35. Pérez AR, Ricucci D, Vieira GCS, Provenzano JC, Alves FRF, Marceliano-Alves MF, et al. Cleaning, shaping, and disinfecting abilities of 2 instrument systems as evaluated by a correlative micro-computed tomographic and histobacteriologic approach. *J Endod*. 2020 Jun;46(6):846-57. doi: 10.1016/j.joen.2020.03.017.
36. Coelho BS, Amaral RO, Leonardi DP, Marques-da-Silva B, Silva-Sousa YT, Carvalho FM, et al. Performance of three single instrument systems in the preparation of long oval canals. *Braz Dent J*. 2016 Mar-Apr;27(2):217-22. doi: 10.1590/0103-6440201302449..
37. Fornari VJ, Silva-Sousa YT, Vanni JR, Pécora JD, Versiani MA, Sousa-Neto MD. Histological evaluation of the effectiveness of increased apical enlargement for cleaning the apical third of curved canals. *Int Endod J*. 2010 Nov;43(11):988-94. doi: 10.1111/j.1365-2591.2010.01724.x.
38. De-Deus G, Belladonna FG, Silva EJ, Marins JR, Souza EM, Perez R, et al. Micro-CT Evaluation of Non-instrumented Canal Areas with Different Enlargements Performed by NiTi Systems. *Braz Dent J*. 2015 Nov-Dec;26(6):624-9. doi: 10.1590/0103-6440201300116.