







# Orthognathic surgery in a patient with von Willebrand disease: case report

Bhárbara Marinho Barcellos<sup>1\*</sup> , Andressa Goicochea  
Moreira<sup>2</sup> , Isabela Toledo Teixeira da Silveira<sup>3</sup> ,  
Eduardo de Freitas Gomes<sup>2</sup> , Cristina Braga Xavier<sup>4</sup> ,  
Otacílio Luiz Chagas Júnior<sup>4</sup> 

<sup>1</sup> Craniofacial Anomalies' Hospital,  
University of São Paulo, Bauru, São  
Paulo, Brazil.

<sup>2</sup> Teaching Hospital, Federal  
University of Pelotas, Pelotas, Rio  
Grande do Sul, Brazil.

<sup>3</sup> School of Dentistry, University of  
São Paulo, Bauru, São Paulo, Brazil.

<sup>4</sup> School of Dentistry of the Federal  
University of Pelotas, Pelotas, Rio  
Grande do Sul, Brazil.

## Corresponding author:

Bhárbara Marinho Barcellos  
Rua Silvio Marchione, 3-20 -  
Vila Nova Cidade Universitária,  
Bauru, São Paulo  
CEP 17012-900  
Phone: (53) 991369307  
E-mail: bharbarambarcellos@  
hotmail.com

**Editor:** Altair A. Del Bel Cury

**Received:** Jan 11, 2023

**Accepted:** Jan 30, 2023

**Aim:** This study aims to report the perioperative management of a patient with von Willebrand disease (vWd) who underwent orthognathic surgery. The report follows the guidelines of the Case Report Guidelines (CARE) and focuses on the steps taken to prevent bleeding during the surgical procedure.

**Methods:** A 39-year-old female patient with skeletal Class III was treated with maxillary advancement and mandibular setback. Despite normal test results for ristocetin cofactor activity, measures were taken to prevent bleeding, including atraumatic surgical techniques, use of antifibrinolytic medication, induced hypotension during anesthesia, and preparation of blood products for transfusion during trans and postoperative periods if needed. In the end, these measures were not required. **Results:** The patient did not experience any bleeding during the surgical procedure or postoperative period, demonstrating the effectiveness of the measures taken to manage their blood dyscrasia. Two years after the surgery, the patient had satisfactory aesthetic and functional results and no evidence of relapse. **Conclusion:** Thus, this case report demonstrates that vWd does not prevent large-scale oral and maxillofacial surgeries such as orthognathic surgery as long as proper precautions are taken pre-, intra- and postoperatively.

**Keywords:** von Willebrand disease. Orthognathic surgery. Case reports.



## Introduction

Von Willebrand Disease (vWd) is recognized as the most frequent hereditary bleeding disorder affecting 0.1%–1% of the general population<sup>1</sup>. It is caused by a deficiency or dysfunction of the von Willebrand factor (vWf), and is classified into three types, with type I being the most prevalent, accounting for up to 70% of all cases<sup>2,3</sup>. The diagnosis of vWd is often suspected during the patient's medical history evaluation, when a history of excessive bleeding episodes such as oral mucosal bleeding, nosebleeds, gum bleeding, excessive bleeding during surgery, and heavy menstrual bleeding is reported<sup>4,5</sup>.

The surgical treatment of vWd patients presents a challenge for the surgeon and the healthcare team due to the increased risk of bleeding during the procedure<sup>6,7</sup>. Orthognathic procedures pose a particular risk, with the majority of blood loss occurring during the manipulation and mobilization of the maxilla during osteotomies<sup>8</sup>. However, there is limited information in the literature on the management of patients with vWd undergoing orthognathic procedures<sup>4,9</sup>. This study aims to provide a comprehensive report, using the Case Report Guidelines (CARE), of the perioperative management and bleeding prevention measures used in a patient with vWd undergoing orthognathic surgery.

## Case report

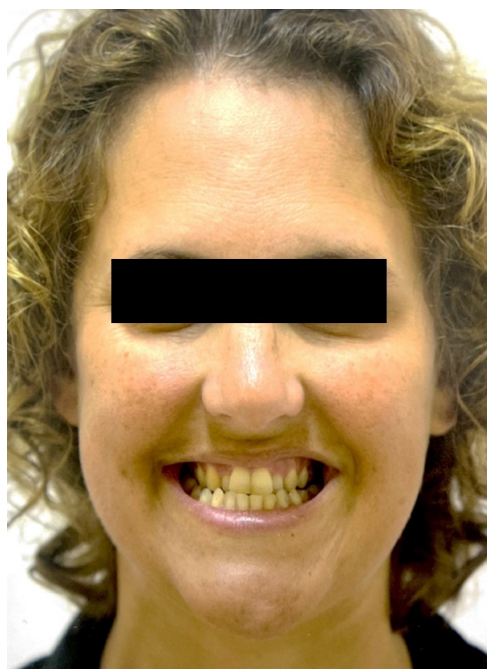A 35-year-old female patient visited the Oral and Maxillofacial Surgery clinic of the Federal University of Pelotas Teaching Hospital for treatment of her facial deformity, as she had been informed that orthognathic surgery was necessary to correct it. The patient had both masticatory dysfunctions and aesthetic complaints. During the medical history review, the patient reported being diagnosed with von Willebrand disease (vWd) at age 13, due to hypermenorrhea and the appearance of ecchymoses and bruises on the body. Additionally, the patient was hospitalized for thrombocytopenia at age 30 and had previous episodes of epistaxis. She also reported having to receive replacement treatment for Factor VIII in the past. The patient is also registered in the database of patients with dyscrasias of the Brazilian Ministry of Health and the Unified Health System.

During the initial consultation, the patient underwent a recent examination (referenced in Table 1) to assess the progression of their condition. This examination included platelet aggregation tests using various aggregating agents such as adenosine diphosphate (ADP), collagen, ristocetin cofactor, ristocetin, adrenaline, and arachidonic acid. The results showed that the patient had moderate low aggregation with collagen and normal aggregation with the other agents. Additionally, the patient's ristocetin cofactor activity was found to be 119%, which falls within the normal range (56%–187%).

**Table 1.** Platelet Aggregation Test

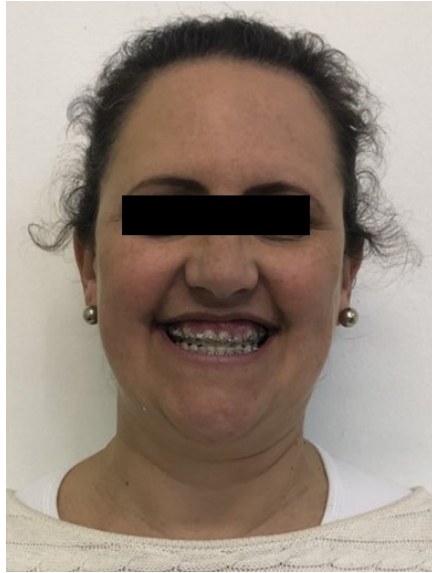Aggregating Agent		Type of Curve	Maximum Aggregation (%)	Reference Values (%)
ADP	10,0 microM	Monophasic	79	73 up to 94
ADP	2,5 microM	Primary with disaggregation	39	14 up to 52
Collagen	5,0 microgramas/mL	-	77	81 up to 96
Collagen	1,0 microgramas/mL	-	79	73 up to 95
Ristocetin	1,2 mg/mL	-	79	77 up to 96
Ristocetin	0,5 mg/mL	-	7	Up to 16
Adrenaline	2,0 microM	Biphasic	80	76 up to 97
Arachidonic Acid	500 microgramas/mL	-	80	80 up to 98

The patient was diagnosed with a skeletal Class III facial deformity, maxillary retrusion, mandibular protrusion, and vertical asymmetry of the maxilla following clinical and imaging evaluations (Figure 1). As a result, the patient was advised to undergo orthodontic-surgical preparation, including dental decompensation and tooth alignment in the bone bases, with an orthodontist following conventional orthognathic surgery.

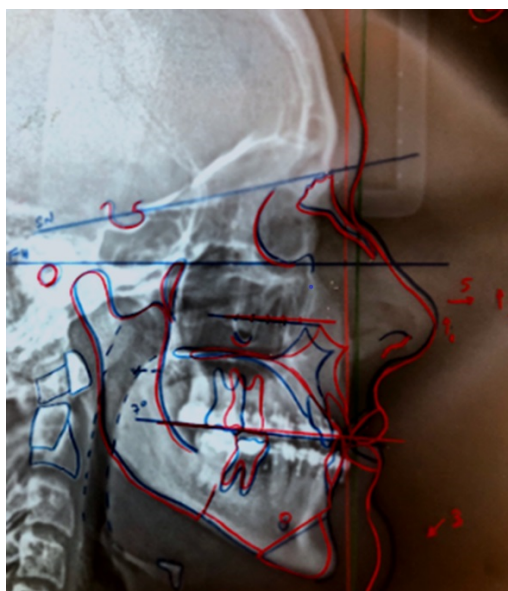**Figure 1.** Initial clinical photography.

The patient received pre-surgical orthodontic treatment for a period of 4 years, under the supervision of the oral and maxillofacial surgery team. At the age of 39, after the comple-

tion of orthodontic treatment, she returned to the service for further evaluation. The oral and maxillofacial surgery team performed a molding and study phase of the patient's models, and based on the evaluations, they determined that the patient was suitable for the surgical procedure (Figure 2). Based on the facial analysis, the study of the patient's models, and the cephalometric tracing, the oral and maxillofacial surgery team devised a treatment plan including bimaxillary orthognathic surgery with 3 mm mandibular set-back, 5 mm maxillary advancement. and 2 mm maxillary impaction (Figure 3).



**Figure 2.** Preoperative photography.



**Figure 3.** Cephalometric surgical planning.

In the immediate preoperative period, laboratory tests were requested (Table 2). The patient was not taking any medication as the condition had stabilized. Despite being routinely monitored by a hematologist, the hematology team at the hospital requested evaluation and monitoring of the patient where the surgery would be performed. The laboratory test results showed no abnormalities, however, for precautionary measures, reserving blood products (blood, plasma, and platelets) prior to the surgery was recommended. Based on the patient's weight of 94 kg, 9 units of platelet concentrate, and 10 units of cryoprecipitate were requested from the hospital's blood bank.

**Table 2.** Preoperative Laboratory Tests

Hemoglobin	13.4 g/dL
Hematocrit	41.8 %
Prothrombin Time	100%/1.0 sec
Partial Thromboplastin Time	21 sec
Platelets	192.000/mm <sup>3</sup>

Orthognathic surgery was performed using conventional techniques, beginning with the maxilla using the Le Fort I osteotomy and concluding with the mandible using the Bilateral Sagittal Split Mandibular osteotomy. Prior to incisions, the mucosa was infiltrated with 10 ml of ropivacaine 0.5%. The surgery lasted 5 hours and 15 minutes, and electrocautery was used for making incisions and for punctual coagulation throughout the procedure. Both the surgeon and the assistant took care in handling the tissues and maintaining a clear operative field.

Furthermore, the anesthesiology team was tasked with keeping the patient in a state of induced hypotension during the surgery, with a target mean arterial pressure of 80 to 50 mmHg. Careful monitoring was exercised during the manipulation of the maxillary area, ensuring that blood pressure was kept at the lowest possible level. In addition to this maneuver, throughout the surgical procedure, complementary hemostasis was achieved via the placement of wet gauze pads on the incisions. The anesthesiology team reported administration of 1g of tranexamic acid, with only 2,000 mL of 0.9% saline solution administered intraoperatively. Vasopressor use was not deemed necessary.

Postoperative facial CT scan revealed proper alignment of the osteosynthesis plates and no evidence of adverse fractures. On the third postoperative day, a minor episode of anterior nasal mucosal bleeding occurred, but no posterior nasal bleeding was detected. Bleeding was effectively managed through localized compression techniques.

There was no requirement for antifibrinolytic therapy, von Willebrand disease-specific medication, or blood transfusion during the postoperative course. The patient was discharged on the fourth postoperative day with stable clinical status, demonstrating proper wound healing and no signs of infection. The patient was instructed on post-operative care, including head elevation, oral hygiene, and a soft diet.

Routine follow-up evaluations were conducted initially twice a week for 1 month, then bi-monthly for 3 months, every 6 months, and annually. Thirty days post-procedure, the patient was discharged for completion of orthodontic treatment. Two years after the surgery, the patient presented without orthodontic appliance, exhibiting functional and aesthetic improvement, including the resolution of chin and lower lip paresthesia (Figure 4), and no indications of relapse.



**Figure 4.** 2 years postoperative clinical photography.

## Discussion

The literature rarely addresses the management of patients with von Willebrand Disease (vWd) undergoing oral and maxillofacial surgical procedures. Previous studies have primarily focused on the perioperative considerations in patients with vWd undergoing simple extractions or other minor oral surgeries<sup>10-12</sup>, with limited and dated reports of patients undergoing more complex facial procedures such as orthognathic or panfacial trauma surgeries<sup>9</sup>. This report aims to fill this gap by offering a discussion on the management and care of patients with vWd undergoing orthognathic surgery.

According to the O'Donnell and Lavin<sup>13</sup> (2019) surgical risk stratification for patients with vWd, procedures involving mucosa are associated with an increased risk of transoperative hemorrhages (Table 3). Despite major oral and maxillofacial procedures not being included in the classification, certain intraoperative features, such as extended surgical duration and manipulation of highly vascularized bone structures, allow for comparison with major orthopedic surgical procedures. It is important to highlight that the restricted operative field due to limited mouth opening exacerbates the challenge of controlling bleeding in case of uncontrolled bleeding.

**Table 3.** Surgical Risk Stratification

Surgical Category	Examples
<b>Major</b>	Neurosurgical procedures
	Laparotomy
	Prostatectomy
	Tonsillectomy
	Hysterectomy
	<b>Orthopedic</b>
<b>Minor</b>	Cesarean
	Biopsy: breast, cervical
	Complicated dental extractions
	Gingival surgery
<b>Single treatment if uncomplicated</b>	Laparoscopic procedures
	Cataract surgery
	Endoscopy (without biopsy)
	Simple dental extractions

O'Donnell and Lavin<sup>13</sup>, 2019.

The literature presents various strategies and techniques aimed at reducing intraoperative and postoperative bleeding. Piñero-Aguilar et al.<sup>14</sup> (2011) conducted a systematic review that showed that the volume of intraoperative bleeding in patients undergoing maxillary or mandibular osteotomies, or a combination thereof was lower than the minimum threshold for blood transfusions, when local compression techniques, anesthesia with induced hypotension, and antifibrinolytic medications were used. The surgeon's technical ability and experience also play a role, as demonstrated by Yu et al.<sup>15</sup> (2000), who emphasized that blood loss during bimaxillary orthognathic surgery is directly proportional to the surgical time and extent of the procedure. Similarly, Dhariwal et al.<sup>16</sup> (2004) reported that the estimated blood loss in normoreactive patients undergoing bimaxillary osteotomies ranges from 50 to 500 mL, and this level of loss can be reduced by up to 50% when induced hypotension is used during anesthesia<sup>17-19</sup>. In the present case, induced hypotension was used during the anesthetic procedure, resulting in minimal recorded blood loss, highlighting its value.

Yawn et al.<sup>20</sup> (2009) proposed three strategies for perioperative care in patients with vWd in an anesthesia guide. These strategies include enhancing plasma circulating vWf through administration of desmopressin, optimizing hemostasis with tranexamic acid or antifibrinolytic medication, and transfusion of blood products. Desmopressin is more effective for patients with type I and type IIA vWd but is not therapeutic for type III. The standard dose of desmopressin, as per Petrovich and Drummond<sup>21</sup> (2004), is 0.3 mcg/kg infused IV over 30 minutes, 24 hours prior to surgery<sup>22</sup>. The recommended prophylactic dose of tranexamic acid is 10--15 mg/kg, IV every 12 hours, 24 hours prior to surgery<sup>23,24</sup>. However, specifically for oral and maxillofacial surgeries, tranexamic acid is the preferred choice and can only be administered intraoperatively at a dose between 10–20 mg/kg IV<sup>25</sup>. Other study found that a single dose of



tranexamic acid given two hours prior to the start of orthognathic surgery can effectively reduce the volume of intraoperative bleeding by approximately one-third<sup>26</sup>. Our patient received 1g of tranexamic acid during their intraoperative care, administered by the anesthesiology team.

Replacement therapies aim to correct vWf deficiency and enhance available Factor VIII levels. Platelet transfusions are the primary method to address platelet defects in cases where desmopressin therapy proves inadequate<sup>27</sup>. The therapeutic choice depends on the severity and type of vWd and the patient's bleeding potential at the time of treatment. In the present case, the patient was in a hemodynamically stable and controlled condition, which were prerequisites for undergoing an elective procedure of the extent of orthognathic surgery. Therefore, there was no need for preoperative transfusions and/or replacements prior to the procedure.

In patients with vWd, general anesthesia is the preferred anesthetic technique<sup>27</sup>. Furthermore, the use of induced hypotension helps to minimize intraoperative bleeding and enhances visibility for the surgeon during the procedure<sup>28,29</sup>. A retrospective study conducted by Carlos et al.<sup>19</sup> (2014) involving 50 patients undergoing orthognathic surgery found that the use of induced hypotension eliminated the need for blood transfusions during the procedure. Additionally, the study concluded that induced hypotension was also effective in reducing the incidence of transient bradycardia during maxillary mobilization. Schaberg et al.<sup>27</sup> (1976) suggests that a mean arterial pressure of 80 mmHg is a clinically acceptable parameter during orthognathic surgery while undergoing induced hypotension. This principle was upheld by the anesthesiology team in the presented case, as the patient's mean arterial pressure was maintained at 80 × 50 mmHg, with the highest peak reaching 110 × 70 mmHg at the beginning of the procedure.

As previously mentioned, the prevention of bleeding during surgical procedures in patients with vWd can be effectively achieved through the use of antifibrinolytic medications, such as aminocaproic acid and tranexamic acid. These drugs prevent the breakdown of the hemostatic plug, particularly in cases of mucosal bleeding<sup>28,29</sup>. In a study involving 23 vWd patients who underwent procedures such as tonsillectomy, adenoidectomy, parotidectomy, thyroidectomy, Zulfikar et al.<sup>5</sup> (2016) found that tranexamic acid was the preferred antifibrinolytic for mucocutaneous surgeries, including multi-tooth extractions.

The advancement of surgical techniques, particularly in the field of orthognathic surgery, is deemed a valuable method to minimize blood loss during procedures. The inferior alveolar nerve (IAN) is frequently damaged during bilateral sagittal mandibular ramus osteotomy<sup>23</sup>, resulting in decreased sensation of the lower lip and chin region. To enhance the visualization of the IAN during orthognathic surgery, a local anesthetic with a vasoconstrictor can be used to infiltrate the nerve's pathway. This not only improves visualization, but also reduces bleeding in the area. A clinical study by Espitalier et al.<sup>30</sup> (2011) supported the use of 5 mL of 0.5% ropivacaine on each side for bilateral IAN block, which effectively decreased bleeding and improved the identification and preservation of the nerve.



Furthermore, the reduction of intraoperative bleeding during orthognathic surgery is a crucial factor for its success. Thus, preoperative planning with the selection of appropriate surgical materials is fundamental when performing osteotomies. According to Pagotto et al.<sup>31</sup> (2017) and Alrefai et al.<sup>32</sup> (2022), the use of piezoelectric technology reduces the volume of intraoperative bleeding and the risk of injury to the IAN. However, Spinelli et al.<sup>33</sup> (2014) and Rossi et al.<sup>34</sup> (2018) have shown that in cases of bimaxillary orthognathic surgery, the surgical time is significantly longer when using piezoelectric technology compared to conventional saws. This can be a disadvantage for patients with vWd, as controlling surgical time is crucial to prevent excessive bleeding. This is supported by the findings of Varol et al.<sup>8</sup> (2010), who state that there is a positive correlation between blood loss and surgical duration, and the skill and experience of the surgeon also play a role. In the present case, the use of a conventional saw did not compromise surgical precision and the duration of the surgery was satisfactory, resulting in no bleeding complications. The importance of combining electrocautery and local compression techniques is emphasized.

In cases of excessive bleeding, the multidisciplinary team must be equipped to perform blood transfusions. The American Society of Anesthesiology established guidelines in 2015, which state that blood products should be transfused in patients with VWD (vWd) who have hemoglobin levels below 8g/dL and hematocrit below 25%, with a priority for cryoprecipitate transfusions. In addition to routine blood counts and coagulograms, platelet aggregation tests, specifically the activity of the ristocetin cofactor, are critical in monitoring patients with vWd<sup>35,36</sup>. This test evaluates the ability of von Willebrand factor (vWf) to cause platelet clumping when activated by the antibiotic ristocetin<sup>37,38</sup> and is regularly performed in cases of blood disorders. In addition to demonstrating normal levels of ristocetin cofactor activity, laboratory tests (Table 2) indicated that the patient had a stable hemodynamic condition, within normal ranges for hemoglobin and hematocrit. However, for precautionary measures, the hematology team reserved cryoprecipitate in case of any complications during the pre- and postoperative periods, which was not necessary. Furthermore, the risk of potential complications from blood transfusions, such as anaphylaxis, acute lung injury associated with transfusion, circulatory overload associated with transfusion (volume overload/hypervolemia), and the low but possible risk of contracting infections such as HIV were also avoided<sup>39,40</sup>.

In rare cases, vWd is categorized as an acquired syndrome that is secondary to malignancies, mainly lymphoproliferative and myeloproliferative diseases, or autoimmune diseases<sup>40</sup>. The differential diagnosis involves evaluating any present comorbidities and the patient's history of bleeding, which is typically negative for the acquired form of vWd<sup>41</sup>. During initial consultations and follow-up appointments, it is crucial to assess the recurrence of hemorrhagic episodes after any invasive procedures.

The limitations of the presented case include the unavailability of the initial diagnostic documentation for vWd due to the diagnosis having been made in 1994. The patient was unable to provide the examination records from the time when she visited our service. Additionally, as the hospital providing the treatment is a public service hospital with limited access to technological resources, it was not possible to use digital flow programs, cutting guides, or other minimally invasive technologies

typically used in orthognathic surgery. Despite these limitations, the surgical technique used was successful.

The preoperative hematological assessment of blood products played a crucial role in ensuring the safe management of the surgical case, ultimately leading to the absence of the need for transfusion. This was achieved using techniques that effectively reduced bleeding during the procedure, thereby maintaining hemodynamic stability. This stability was further evidenced by the anesthesiology team's decision not to administer any vasopressor medications during or after the surgery. These measures, commonly used to control bleeding in normal patients, are also applicable and recommended for patients with VWD, after a thorough clinical and hematological evaluation. The case serves as an important reminder of the importance of proper documentation in medical records and the importance of multidisciplinary teamwork, especially when caring for patients with special needs.

The patient has expressed high levels of satisfaction with the outcome of the surgery. She now experiences a heightened sense of confidence in smiling and has developed a fondness for taking photographs. The patient also mentions the comfort and security provided by the surgical team throughout the procedure.

In general, it is essential to carefully assess the patient's medical status and potential risks involved in any surgical procedure. Adequate measures should be taken to ensure the patient's safety, such as inducing hypotension during anesthesia and administering antifibrinolytic medications. This case report demonstrates that vWD does not pose a barrier to the performance of major oral and maxillofacial surgical procedures, such as orthognathic surgery, provided that the necessary precautions are taken pre-, intra- and postoperatively.

## Data availability

Datasets related to this article will be available upon request to the corresponding author.

## Conflicts of interest statement

The authors report no conflicts of interest in this case report.

## Author Contribution

All the authors actively participated during this work production, as the author and all co-authors were engaged in the clinical case research, manuscript's construction, writing, revision, and final approval. Bhárbara Marinho Barcellos participated in the surgical planning, surgery and patient's follow-up, also was responsible for the data collection and manuscript writing and final approval. Andressa Goicochea Moreira participated in the patient follow-up, manuscript writing and revision. Isabela Toledo participated in the manuscript findings, writing, revision, and format for final approval. Eduardo Gomes was also responsible for the manuscript writing and data base research, also for the final approval of the article. Cristina Xavier was responsible for guiding the data collection, manuscript writing, revising, and approving the final ver-

sion. Otacilio Chagas was the main surgeon of the case, also responsible for the manuscript's findings and guiding the correct writing of the events.

---

## References

1. Sadler JE, Mannucci PM, Berntorp E, Bochkov N, Boulyjenkov V, Ginsburg D, et al. Impact, diagnosis and treatment of von Willebrand disease. *Thromb Haemost*. 2000 Aug;84(2):160-74.
2. Keeney S, Cumming AM. The molecular biology of von Willebrand disease. *Clin Lab Haematol*. 2001 Aug;23(4):209-30. doi: 10.1046/j.1365-2257.2001.00400.x.
3. Sadler JE. Biochemistry and genetics of von Willebrand factor. *Ann Rev Biochem*. 1998;67:395-424.
4. Wilde JT, Cook RJ. von Willebrand disease and its management in oral and maxillofacial surgery. *Br J Oral Maxillofac Surg*. 1998 Apr;36(2):112-8. doi: 10.1016/s0266-4356(98)90178-4.
5. Zulfikar B, Koc B, Ak G, Dikici F, Karaman İ, Atalar AC, et al. Surgery in patients with von Willebrand disease. *Blood Coagul Fibrinolysis*. 2016 Oct;27(7):812-6. doi: 10.1097/MBC.0000000000000500.
6. Olsen JJ, Skov J, Ingerslev J, Thorn JJ, Pinholt EM. Prevention of bleeding in orthognathic surgery—a systematic review and meta-analysis of randomized controlled trials. *J Oral Maxillofac Surg*. 2016 Jan;74(1):139-50. doi: 10.1016/j.joms.2015.05.031. Erratum in: *J Oral Maxillofac Surg*. 2017 Sep;75(9):2027-2030.
7. Mei A, Qiu L. The efficacy of tranexamic acid for orthognathic surgery: a meta-analysis of randomized controlled trials. *Int J Oral Maxillofac Surg*. 2019 Oct;48(10):1323-8. doi: 10.1016/j.ijom.2018.07.027.
8. Varol A, Basa S, Ozturk S. The role of controlled hypotension upon transfusion requirement during maxillary downfracture in double-jaw surgery. *J Craniomaxillofac Surg*. 2010 Jul;38(5):345-9. doi: 10.1016/j.jcms.2009.10.012.
9. Ilankovan V, Blesing NE, Moos KF, Davidson JF. Correction of facial deformities in patients with mild bleeding disorders: a report of three cases. *Br J Oral Maxillofac Surg*. 1990 Dec;28(6):398-400. doi: 10.1016/0266-4356(90)90038-m.
10. Nickles K, Wohlfeil M, Alesci S, Miesbach W, Eickholz P. Comprehensive treatment of periodontitis in patients with von Willebrand disease. *J Periodontol*. 2010 Oct;81(10):1432-40. doi: 10.1902/jop.2010.100076.
11. Malmquist JP. Complications in oral and maxillofacial surgery: management of hemostasis and bleeding disorders in surgical procedures. *Oral Maxillofac Surg Clin North Am*. 2011 Aug;23(3):387-94. doi: 10.1016/j.coms.2011.04.006.
12. van Galen KP, Engelen ET, Mauser-Bunschoten EP, van Es RJ, Schutgens RE. Antifibrinolytic therapy for preventing oral bleeding in patients with haemophilia or Von Willebrand disease undergoing minor oral surgery or dental extractions. *Cochrane Database Syst Rev*. 2019 Apr;4(4):CD011385. doi: 10.1002/14651858.CD011385.pub3.
13. O'Donnell JS, Lavin M. Perioperative management of patients with von Willebrand disease. *Hematology Am Soc Hematol Educ Program*. 2019 Dec 6;2019(1):604-9. doi: 10.1182/hematology.2019000065.
14. Piñeiro-Aguilar A, Somoza-Martín M, Gandara-Rey JM, García-García A. Blood loss in orthognathic surgery: a systematic review. *J Oral Maxillofac Surg*. 2011 Mar;69(3):885-92. doi: 10.1016/j.joms.2010.07.019.
15. Yu CN, Chow TK, Kwan AS, Wong SL, Fung SC. Intra-operative blood loss and operating time in orthognathic surgery using induced hypotensive general anaesthesia: prospective study. *Hong Kong Med J*. 2000 Sep;6(3):307-11.

16. Dhariwal DK, Gibbons AJ, Kittur MA, Sugar AW. Blood transfusion requirements in bimaxillary osteotomies. *Br J Oral Maxillofac Surg.* 2004 Jun;42(3):231-5. doi: 10.1016/j.bjoms.2003.11.001.
17. McNulty S, Sharifi-Azad S, Farole A. Induced hypotension with labetalol for orthognathic surgery. *J Oral Maxillofac Surg.* 1987 Apr;45(4):309-11. doi: 10.1016/0278-2391(87)90349-1.
18. Praveen K, Narayanan V, Muthusekhar MR, Baig MF. Hypotensive anaesthesia and blood loss in orthognathic surgery: a clinical study. *Br J Oral Maxillofac Surg.* 2001 Apr;39(2):138-40. doi: 10.1054/bjom.2000.0593.
19. Carlos E, Monnazzi MS, Castiglia YM, Gabrielli MF, Passeri LA, Guimarães NC. Orthognathic surgery with or without induced hypotension. *Int J Oral Maxillofac Surg.* 2014 May;43(5):577-80. doi: 10.1016/j.ijom.2013.10.020.
20. Yawn B, Nichols WL, Rick ME. Diagnosis and management of von Willebrand disease: guidelines for primary care. *Am Fam Physician.* 2009 Dec 1;80(11):1261-8.
21. Petrovich CT, Drummond JC. [Hemoterapia e hemostasia], In: Barash PG, Cullen BF, Stoelting RK. [Anestesia Clínica]. 4. ed. São Paulo: Manole; 2004. p.201-8. Portuguese
22. Flores RPG, Bagatini A, Santos TL, Gomes CR, Fernandes MS, Molon RP. Hemophilia and anesthesia. *Braz J Anesthesiol.* 2004;54(6):865-71. doi: 10.1590/S0034-70942004000600017.
23. Kim SG, Park SS. Incidence of complications and problems related to orthognathic surgery. *J Oral Maxillofac Surg.* 2007 Dec;65(12):2438-44. doi: 10.1016/j.joms.2007.05.030.
24. Barbosa FT, Cunha RM, Barbosa LT. Von Willebrand's disease and anesthesia. *Braz J Anesthesiol.* 2007;57(3):315-23. doi: 10.1590/S0034-70942007000300010.
25. Dolman RM, Bentley KC, Head TW, English M. The effect of hypotensive anesthesia on blood loss and operative time during Le Fort I osteotomies. *J Oral Maxillofac Surg.* 2000 Aug;58(8):834-9; discussion 840. doi: 10.1053/joms.2000.8194.
26. Grando TA, Puricelli E, Chiao IU, Mesquita DIC. [Hipotensão induzida e controlada pelo halotano e nitroprussiato de sódio na cirurgia ortognática]. *Rev Bras Anesthesiol.* 1990;40(5):325-30. Portuguese.
27. Schaberg SJ, Kelly JF, Terry BC, Posner MA, Anderson EF. Blood loss and hypotensive anesthesia in oral-facial corrective surgery. *J Oral Surg.* 1976 Feb;34(2):147-56.
28. Nichols WL, Hultin MB, James AH, Manco-Johnson MJ, Montgomery RR, Ortel TL, et al. von Willebrand disease (VWD): evidence-based diagnosis and management guidelines, the National Heart, Lung, and Blood Institute (NHLBI) Expert Panel report (USA). *Haemophilia.* 2008 Mar;14(2):171-232. doi: 10.1111/j.1365-2516.2007.01643.x.
29. Kouides PA, Byams VR, Philipp CS, Stein SF, Heit JA, Lukes AS, et al. Multisite management study of menorrhagia with abnormal laboratory haemostasis: a prospective crossover study of intranasal desmopressin and oral tranexamic acid. *Br J Haematol.* 2009 Apr;145(2):212-20. doi: 10.1111/j.1365-2141.2009.07610.x.
30. Espitalier F, Remerand F, Dubost AF, Laffon M, Fuscuardi J, Goga D. Mandibular nerve block can improve intraoperative inferior alveolar nerve visualization during sagittal split mandibular osteotomy. *J Craniomaxillofac Surg.* 2011 Apr;39(3):164-8. doi: 10.1016/j.jcems.2010.04.015.
31. Pagotto LEC, de Santana Santos T, de Vasconcellos SJA, Santos JS, Martins-Filho PRS. Piezoelectric versus conventional techniques for orthognathic surgery: Systematic review and meta-analysis. *J Craniomaxillofac Surg.* 2017 Oct;45(10):1607-13. doi: 10.1016/j.jcems.2017.06.011.
32. Alrefai M, Daboul A, Fleischhacker B, Landes C. Piezoelectric versus conventional techniques for orthognathic surgery: Systematic review and meta-analysis. *J Stomatol Oral Maxillofac Surg.* 2022 Oct;123(5):e273-8. doi: 10.1016/j.jormas.2021.12.005.

33. Spinelli G, Lazzeri D, Conti M, Agostini T, Mannelli G. Comparison of piezosurgery and traditional saw in bimaxillary orthognathic surgery. *J Craniomaxillofac Surg*. 2014 Oct;42(7):1211-20. doi: 10.1016/j.jcms.2014.02.011.
34. Rossi D, Romano M, Karanxha L, Baserga C, Russillo A, Taschieri S, et al. Bimaxillary orthognathic surgery with a conventional saw compared with the piezoelectric technique: a longitudinal clinical study. *Br J Oral Maxillofac Surg*. 2018 Oct;56(8):698-704. doi: 10.1016/j.bjoms.2018.07.011.
35. Echahdi H, El Hasbaoui B, El Khorassani M, Agadr A, Khattab M. Von Willebrand's disease: case report and review of literature. *Pan Afr Med J*. 2017 Jun;27:147. doi: 10.11604/pamj.2017.27.147.12248.
36. James PD, Goodeve AC. von Willebrand disease. *Genet Med*. 2011 May;13(5):365-76. doi: 10.1097/GIM.0b013e3182035931.
37. Napolitano LM, Kurek S, Luchette FA, Corwin HL, Barie PS, Tisherman SA, et al. Clinical practice guideline: red blood cell transfusion in adult trauma and critical care. *Crit Care Med*. 2009 Dec;37(12):3124-57. doi: 10.1097/CCM.0b013e3181b39f1b. Erratum in: *Crit Care Med*. 2010 Jul;38(7):1621.
38. Goodnough LT, Panigrahi AK. Blood transfusion therapy. *Med Clin North Am*. 2017 Mar;101(2):431-47. doi: 10.1016/j.mcna.2016.09.012.
39. Aubron C, Aries P, Le Niger C, Sparrow RL, Ozier Y. How clinicians can minimize transfusion-related adverse events? *Transfus Clin Biol*. 2018 Nov;25(4):257-61. doi: 10.1016/j.tracli.2018.08.158.
40. Mital A. Acquired von Willebrand Syndrome. *Adv Clin Exp Med*. 2016 Nov-Dec;25(6):1337-44. doi: 10.17219/acem/64942.
41. Federici AB. Acquired von Willebrand syndrome: an underdiagnosed and misdiagnosed bleeding complication in patients with lymphoproliferative and myeloproliferative disorders. *Semin Hematol*. 2006 Jan;43(1 Suppl 1):S48-58. doi: 10.1053/j.seminhematol.2005.11.003.