





# Combination of phototherapy for treatment of labial necrotizing lesion: case report

Elaine Aparecida Rocha Domingues<sup>1\*</sup> , Lana Luiza da Cruz Silva<sup>2</sup> , Marcelly Silva Dourado<sup>3</sup> , Cintia Teles de Argôlo<sup>4</sup> 

<sup>1</sup> Stomatherapist Nurse from the Albert Einstein Israelite Institute of Education and Research. PhD in Health Sciences from the University of Campinas (Unicamp). Campinas, São Paulo, Brazil.

<sup>2</sup> Dermatologist at the University of São Paulo (USP). PhD in Health Sciences from USP. São Paulo, Brazil.

<sup>3</sup> Stomatherapist Nurse from the Albert Einstein Israelite Institute of Education and Research. Specialist in Dermatology Nursing from the Dom Alberto College (FDA). Aracajú, Sergipe, Brazil.

<sup>4</sup> PhD in Applied Biomolecular Physics from the University of São Paulo (USP). Professor at the Sergipe Physics Institute, Aracajú, Sergipe, Brazil.

## Corresponding author:

Elaine Aparecida Rocha Domingues  
Email: elainerocha.contato@gmail.com  
Endereço: Travessa Costa de Lavos, 59, Panamá, Campo Grande – MS.  
Telefone: 35 9888800905

**Editor:** Altair A. Del Bel Cury

**Received:** Feb 01, 2023

**Accepted:** Aug 22, 2023

Lip necrotizing lesions are painful, complex to heal, and negatively impact the patient's orofacial condition. The present study reports a clinical case of a necrotizing lesion on the lower lip in a 38-year-old male patient, previously healthy, five days after receiving the first dose of the SARS-COV-2 vaccine, with an initial diagnosis of labial herpes zoster, with secondary infection and unsatisfactory response to clinical treatment. After debridement of the necrotic tissue, followed by a combination of antimicrobial photodynamic therapy (aPDT), photobiomodulation therapy (PBMT) and hydrofiber dressing with silver, the patient evolved with complete healing of the lip lesion and satisfactory restoration of orofacial functions after 7 days. According to the present case report, this combination of phototherapy modalities suggests to be a promising tool for the treatment of necrotizing labial lesions.

**Keywords:** Lip diseases. Low-level light therapy. Photochemotherapy.



## Introduction

Lips are two muscle folds, formed from skeletal striated muscle, and covered on their three sides. Externally, it is covered with skin. The intermediate portion, known as the red zone of the lip, presents a slightly keratinized stratified squamous epithelium, whose adjacent connective tissue is richly supplied with blood vessels. Finally, the inner face is covered by the oral mucosa<sup>1</sup>.

Acute and chronic injuries are frequently reported in the oral mucosa. Some lesions are easier to be detected clinically, while others are more difficult to be diagnosed<sup>2</sup>.

Ulceration is a disruption of the oral epithelium that normally exposes the nerve endings in the underlying lamina propria, resulting in pain<sup>2</sup>. Avulsive lesions of the lip with significant tissue loss represent the most difficult cases for repair, requiring specialized reconstructive techniques<sup>3</sup>.

Oral ulcers are frequent in the general population and can have different etiologies, such as traumatic, infectious, inflammatory, neoplastic, in addition to idiopathic causes. Although common, accurate etiological diagnosis can still be a great challenge<sup>4</sup>.

Lip necrotizing lesions are rare, usually associated with infections of the oral cavity or secondary to surgery, trauma or cosmetic procedures, due to vascular occlusion in lip filling<sup>5-6</sup>. Group A beta-hemolytic streptococci and staphylococci are considered the main causative agents<sup>5</sup>.

Tissue repair of injuries occurs through the healing process that ranges from hemostasis to the remodeling of newly formed tissues. Due to the complexity of the cellular and molecular events involved in healing and the delaying factors, the choice of healing therapy must suit the characteristics presented by the wound, since its evolution is dynamic<sup>7-8</sup>.

Silver hydrofiber dressings act to control moisture, favoring a moist environment suitable for healing and action against pathogenic microorganisms due to the action of nanocrystallized silver. Studies have shown an important antimicrobial activity of this dressing against aerobic and anaerobic pathogens, including, fungi and antibiotic-resistant bacteria<sup>9</sup>.

Combined therapies that favor tissue repair may, in this context, enhance the effects of the treatment, leading to an accelerated and less painful healing process. Thus, the use of photonic therapies has gained ground for wound treatment, either as supporting therapies or main therapies, as they promote adequate conditions for the effective healing process.

Photodynamic therapy (PDT) works to combat *in situ* pathogenic microorganisms, such as viruses and bacteria. According to Tardivo (2014), PDT is a treatment modality that uses light combined with a photosensitizing agent (FS) to generate *in situ* reactive oxygen species (ROS), which cause cell death. First, FS is applied in the region to be treated and waits for a period necessary for the penetration and accumulation of the drug. After the incubation time, the region is irradiated with light at the appropriate wavelength to be absorbed by the FS, leading to the formation of ROS and subsequent death of the treated cell<sup>10</sup>.

Photobiomodulation (PBM) trigger the healing cascade through the production of ATP, thus favoring faster wound closure. According to Hamblin<sup>11</sup>, photobiomodulation involves the use of red or near infrared light at low power densities to produce a ben-

eficial effect on cells or tissues. PBM therapy is used to reduce pain, inflammation, edema and to regenerate damaged tissue such as wounds, bones and tendons.

One of the most commonly reported actions of PBM is the induction of angiogenesis, as observed during wound healing studies, this event occurs because the cells have moderate levels of hypoxia, as assessed by the actual availability of oxygen to the tissue, but the enzyme mitochondrial cytochrome C oxidase (CCO) is inhibited by bound nitric oxide (NO), so actual oxygen depletion by respiration will be less pronounced than it would have been if CCO had not been inhibited. However, if PBM displaces NO, allowing respiration to resume, then oxygen levels will suddenly drop to very low levels, causing transcription factor HIF1  $\alpha$  to be stabilized and VEGF and other pro-angiogenic mediators to be produced<sup>11</sup>.

As a limitation of the study, it is highlighted that it is a clinical case. As a hypothesis, it is believed that the Combination of phototherapy for treatment of labial necrotizing lesion accelerates the tissue repair process. In this case report, PBM and PDT were used to promote decontamination and more effective healing of the labial necrotizing lesion.

The present study aimed to report a clinical case in which a combination of antimicrobial photodynamic therapy (aPDT), photobiomodulation therapy (PBMT) and hydrofiber dressing with silver in the treatment of extensive ulcerated labial lesion in a previously healthy patient.

## Methods

This was a descriptive case-report study of a patient with a necrotic lesion on the lower lip, initially monitored by telemedicine, due to the context of the COVID-19 pandemic, followed by face-to-face follow-up.

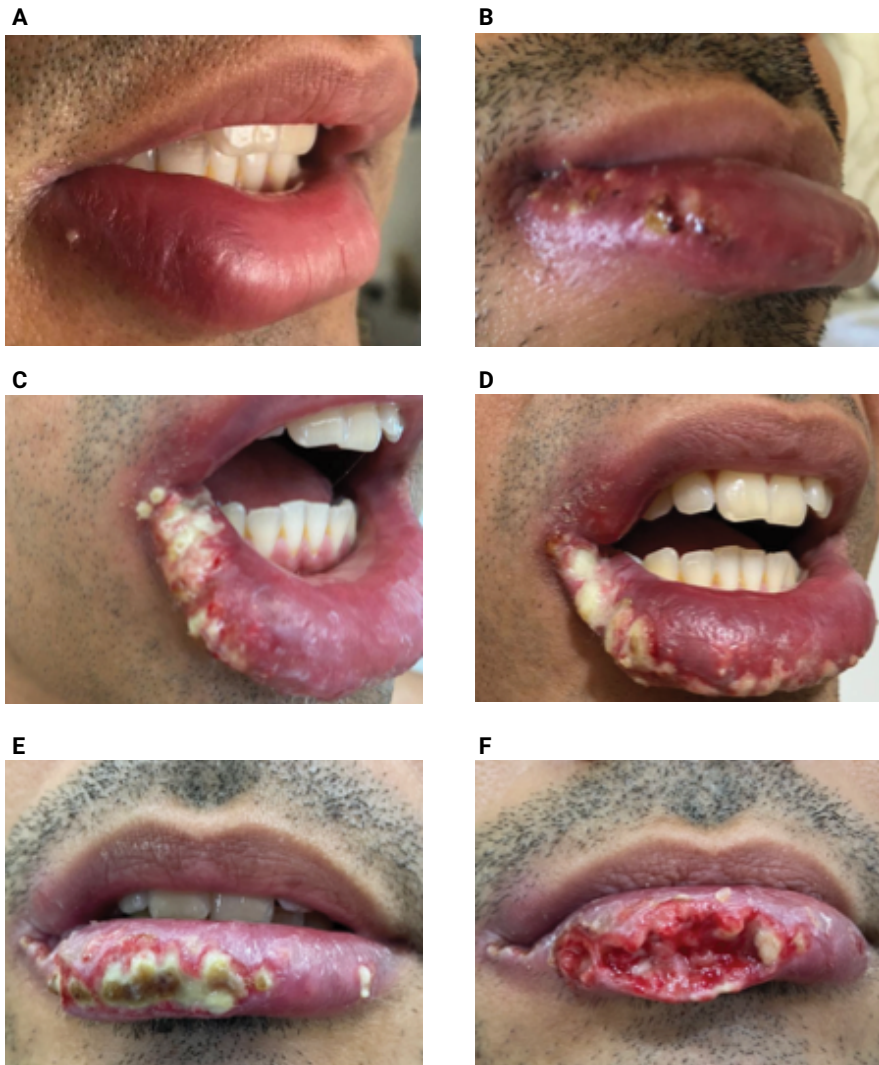Wound care was provided by a professional specialist in dermatological medicine and dermatological nursing from 13/03/2021 to 26/03/2021. Data collection began after approval by the research ethics committee with opinion number 5.072.435.

For data collection, an instrument designed to describe personal and health variables was used, such as: age, gender and education. To follow up on the evolution of the lesion, a photographic record was used through a double camera (ultra-angle and wide-angle) of 12 MP, opening f/2.4 and a field of view of 120°. In addition, measurement was taken using a disposable ruler graduated in centimeters.

For the publication of the study, the patient was remedied and asked to sign the informed consent, in accordance with Resolution 466/2012 of the National Health Council (CNS), which refers to research with human beings, respecting privacy, autonomy and anonymity. This case report was sent to the Research Ethics Committee for consideration and approval.

## Case Report

Brazilian, male, 38 years old, previously healthy, 5 days after receiving the first dose of the vaccine against COVID-19 (AstraZeneca®), started with edema, pain and onset of pustular lesion in the lower lip on the right (figure 1a), evolving with multiple shallow ulcerations in the region (figure 1b). He reported a clinical history of lip herpes. There was no previous history of surgery, allergies or drug reactions.



**Figure 1.** Clinical evolution. (a) Initial vesicle, associated with edema in the lower lip, on the right. (b) Progression of lesions with multiple shallow ulcerations and some covered by hematic crusts, 72 hours after the initial lesion. (c) Worsening of the edema, with pustules and multiple confluent ulcers, with a fibrinous base, reaching the right labial commissure. (d) Progression of lesions along the entire lower lip. (e) Appearance before debridement. (f) Immediate appearance after debridement (note substantial tissue loss in the region).

On the fourth day of evolution, the patient underwent a dermatological evaluation by telemedicine, due to the worsening of the pandemic scenario in Brazil. He was empirically treated with oral valaciclovir (500mg 12/12 hours) and received an intramuscular dose of the combination of betamethasone dipropionate and betamethasone disodium phosphate for the treatment of herpes simplex.

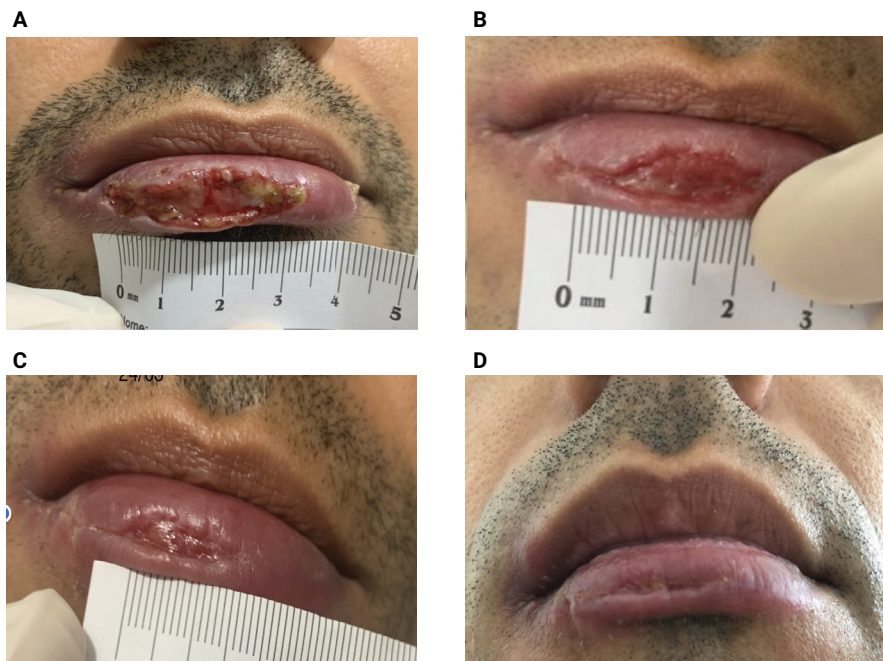
Despite the treatment instituted, after 24 hours, the lesions worsened (figure 1c), and the dose of valaciclovir was then adjusted to 1g 8/8 hours, combined with amoxicillin-clavulanate 875/125mg (12/12 hours) and prednisone 40mg/day, for clinical suspicion of herpes zoster with secondary bacterial infection.

In the laboratory investigation, he presented complete blood count within the normal range, VHS: 33mm/h (1st hour), ultrasensitive PCR: 1.33 mg/L, FAN: non-reactive, serology for COVID-19 (chemiluminescence), herpes simplex 1- 2, varicella-zoster, cytomegalovirus, coxsackie B (1-6), coxsackie A9 were all IgM negative and IgG positive, and serologies for HIV and viral hepatitis were all negative.

The patient evolved with reduced pain and lip edema, however, the appearance of pustules along the lower lip remained (figure 1d), despite remaining afebrile. Due to the extent of the lesions, a face-to-face dermatological evaluation was requested, observing the confluence of the pustules in the lower lip, purulent discharge in the distal portion on the left, in addition to a scar area in the labial commissure on the right (figure 1e). The patient's oral cavity was carefully examined, showing good oral hygiene and no odontogenic foci. No cervical lymphadenopathy was found on clinical examination.

Mechanical debridement of the devitalized tissue was performed, resulting in an extensive deep ulcer in the lower lip (figure 1f). Then, the patient was referred for follow-up with specialized dermatological nursing, maintaining the use of valaciclovir (07 days) and amoxicillin-clavulanate (14 days).

From the nursing evaluation, there was a 3+/4+ edema in the lips, presence of extensive lesion measuring 3 cm in length and 1.5 cm in width (total area of 4.5 cm<sup>2</sup>), cavitory, with about 80% slough and 20% granulation, purulent exudation in moderate amount on the lower lip (figure 2a). This condition had an impact on the patient's basic orofacial conditions.



**Figure 2.** Clinical evolution. (a) Labial ulcer with presence of devitalized tissue, associated with edema in the lower lip, on the right. (b) Regression of the lesion with absence of devitalized tissue and improvement in edema 72 hours after PDT. (c) Reduction in lesion size and absence of edema 48 hours after FBM. (d) Epithelialization of the lesion after 7 days of therapy.



A PDT session was performed, with 1% methylene blue SF applied over the entire lesion. Irradiation occurred after an incubation time of 5 minutes, using the EC laser therapy device, with 100 mW of useful power and 660 nm wavelength, in point-to-point contact mode. The treatment used 4 joules of energy, corresponding to a dose of 40 J/cm<sup>2</sup> in just one application point. After PDT, a hydrofiber dressing with silver was used for 48 hours, followed by an application of PBMT every 72 hours.

For photobiomodulation, the same device was used, also in point-to-point contact mode. However, this time using the energy of 1 joule, which corresponds to a dose of 10.16 J/cm<sup>2</sup>, at wavelengths of 660 nm, for the interior of the lesion at 4 points, and 880 nm for the margins at 5 points.

After 7 days of combination of phototherapy and hydrofiber dressing with silver, the labial lesions healed completely and the patient satisfactorily recovered basic orofacial functions (figure 2d).

## Discussion

Patients with necrotizing lesions on the lip usually have some associated comorbidity, such as diabetes mellitus, arteriosclerosis, obesity, malignant neoplasm, hypothyroidism, alcoholism, smoking, cirrhosis, drug abuse, nutritional deficiency or chronic use of corticosteroids<sup>12</sup>. Extensive lower lip necrosis has been described after chin acne infection (necrotizing fasciitis) and after concomitant herpes zoster and herpes simplex-1 labial infection, both in young patients<sup>5,13</sup>. There are also reports of extensive nasal skin necrosis and maxillary osteonecrosis secondary to herpes zoster<sup>14-15</sup>.

Although the diagnoses of herpes simplex and herpes zoster with secondary infection were initially suggested, in oral herpes zoster, the lesions are generally unilateral, extending to the midline and frequently present with involvement of the skin adjacent to the labial mucosa, different from what is observed in the case report described. Herpes zoster oral lesions consist of small vesicles that quickly rupture to form painful superficial ulcers. The presence of extensive necrosis of the surrounding tissue is rare and related to localized vasculitis<sup>13</sup>.

Oral ulcers have also been described as a clinical manifestation of SARS-COV-2 and, less frequently, after vaccination against COVID-19<sup>16-18</sup>. COVID-19-related oral symptoms have been attributed to the high expression of angiotensin-2 converting enzyme (ACE2) receptors on the epithelial cells of the tongue, buccal and gingival mucosa (Riad et al, 2020). Adverse events in the oral cavity have been described for several vaccines, such as those against diphtheria, tetanus, acellular pertussis and poliomyelitis<sup>19</sup>. In a study on the prevalence of side effects after the Pfizer – BioNTech COVID-19 vaccine, in health professionals in the Czech Republic, observed a prevalence of 13% (n=114) of oral side effects. Of these, the most common oral manifestations were blisters (36%), followed by halitosis (25.4%), ulcers (14%), gingival bleeding (11.4%) and white/red plaque (10.5%); the most common location of ulcers, blisters and vesicles is the lips (74.1%). They also noted that most oral side effects started in the first week post-vaccination (28.6%), and could appear within 1-3 days after vaccination (26.8%) or within 4 weeks after vaccine application (9.8%) (Riad A et al, 2021).

In the present case, although it is not possible to make a causal association, it is important to emphasize that the lip ulcers started 5 days after the first dose of the vaccine against COVID-19<sup>17-18</sup>.

Lip lesions were treated with the combination of photodynamic therapy, photobiomodulation and hydrofiber dressing with silver and resulted in an important clinical improvement in the patient's orofacial condition related to labial necrotizing lesion. Considering that PDT proved to be effective in inhibiting bacterial, fungal and viral infections, the present study shows a satisfactory result after an application of this therapy in the lesion. After an application of PDT with a silver hydrofiber dressing, a reduction in purulent exudate and an increase in granulation tissue was observed.

Photobiomodulation (PBM) was performed after ceasing the local infection with PDT and required only 2 applications for complete healing of the lesion.

PBMT, in turn, reduces the concentration of signaling molecules such as nuclear factor-kappa beta and tumor necrosis factor-alpha and inhibits prostaglandin E2, cyclooxygenase-2 and interleukin 1 beta, resulting in analgesia and mitigation of the inflammatory process<sup>20</sup>.

## Conclusion

A case of extensive necrosis of the lower lip, resulting in a major defect in the affected tissue, was presented in a young immunocompetent individual, with no apparent risk factor, after vaccination against COVID-19. Although the etiology of the lesion has not been clearly elucidated, this report praises the combination of phototherapy modalities and hydrofiber dressings with silver as a promising tool for the treatment of labial necrotizing lesions.

## Data Availability

Datasets related to this article will be available upon request to the corresponding author.

## Conflict of interest

No conflicts of interest.

## Author contribution

**Conceptualization:** Elaine Aparecida Domingues, Lana Luiza Cruz Silva, Marcellly Silva Dourado.

**Methodology:** Elaine Aparecida Domingues, Cintia Teles de Argôlo, Marcellly Silva Dourado.

**Research:** Elaine Aparecida Domingues, Lana Luiza Cruz Silva, Marcellly Silva Dourado.

**Writing - First version:** Elaine Aparecida Domingues, Lana Luiza Cruz Silva, Cintia Teles de Argôlo, Marcellly Silva Dourado.

**Writing - Proofreading & Editing:** Elaine Aparecida Domingues, Lana Luiza Cruz Silva, Cintia Teles de Argôlo, Marcellly Silva Dourado.

---

## References

1. Berkovitz BKB, Holland GR, Moxhan BJ. [Anatomy, embryology and oral histology]. 3 ed. São Paulo: Artmed; 2004. Portuguese.
2. Oriá RB, Brito GAC, organizers. [Digestive system: basic-clinical integration]. São Paulo: Blucher; 2016. Portuguese.
3. de Oliveira MP, Martins PDE; da Cunha GL, Alvarez GF, Gazzalle A, Siqueira EJ. Use of the vermilion myomucosal flap with or without the mentolabial skin flap for lower lip reconstruction. *Rev Bras Cir Plast.* 2011;26(3):433-8.
4. Leão JC, Gomes VB, Porter S. Ulcerative lesions of the mouth: an update for the general medical practitioner. *Clinics (Sao Paulo).* 2007 Dec;62(6):769-80. doi: 10.1590/s1807-59322007000600018.
5. Eltayeb AS, Ahmad AG, Elbeshir EI. A case of labio-facial necrotizing fasciitis complicating acne. *BMC Res Notes.* 2016 Apr;9:232. doi: 10.1186/s13104-016-2041-3.
6. Hirsch P, Infanger M, Kraus A. A case of upper lip necrosis after cosmetic injection of hyaluronic acid soft-tissue filler-Does capillary infarction play a role in the development of vascular compromise, and what are the implications? *J Cosmet Dermatol.* 2020 Jun;19(6):1316-20. doi: 10.1111/jocd.13391.
7. Schilrreff P, Alexiev U. Chronic Inflammation in Non-Healing Skin Wounds and Promising Natural Bioactive Compounds Treatment. *Int J Mol Sci.* 2022 Apr;23(9):4928. doi: 10.3390/ijms23094928.
8. Bacci S. Cutaneous wound healing: cellular mechanisms and therapies (an update). *Stefano Bacci. Med Res Arch.* 2019;7(9):1-14.
9. Moser H, Pereima RR, Pereima MJL. [Evolution of silver dressings in the treatment of partial thickness burns]. *Rev Bras Queimad.* 2013;12(2):60-7. Portuguese.
10. Tardivo JP, Adami F, Correa JA, Pinhal MA, Baptista MS. A clinical trial testing the efficacy of PDT in preventing amputation in diabetic patients. *Photodiagnosis Photodyn Ther.* 2014 Sep;11(3):342-50. doi: 10.1016/j.pdpdt.2014.04.007.
11. Hamblin MR. Mechanisms and applications of the anti-inflammatory effects of photobiomodulation. *AIMS Biophys.* 2017;4(3):337-61. doi: 10.3934/biophy.2017.3.337.
12. Zilberstein B, de Cleve R, Testa RS, Sene U, Eshkenazy R, Gama-Rodrigues JJ. Cervical necrotizing fasciitis due to bacterial tonsillitis. *Clinics (Sao Paulo).* 2005 Apr;60(2):177-82. doi: 10.1590/s1807-59322005000200015.
13. McCormick AP, Kanas RJ, Orton M, Rice T. Unusual necrosis of the lower lip following a varicella zoster recurrence. *Int J Oral Dent Health.* 2016;2:016. doi: 10.23937/2469-5734/1510026.
14. Snel BJ, Visconti G, Grabietz PD, Werker PM. Necrosis of nose skin after varicella zoster infection: a case report. *J Plast Reconstr Aesthet Surg.* 2010 May;63(5):e445-7. doi: 10.1016/j.bjps.2009.08.006.
15. Jain MK, Manjunath KS, Jagadish SN. Unusual oral complications of herpes zoster infection: report of a case and review of literature. *Oral Surg Oral Med Oral Pathol Oral Radiol Endod.* 2010 Nov;110(5):e37-41. doi: 10.1016/j.tripleo.2010.04.026.
16. Iranmanesh B, Khalili M, Amiri R, Zartab H, Aflatoonian M. Oral manifestations of COVID-19 disease: A review article. *Dermatol Ther.* 2021 Jan;34(1):e14578. doi: 10.1111/dth.14578.
17. Riad A, Klugar M, Krsek M. COVID-19-Related Oral Manifestations: Early Disease Features? *Oral Dis.* 2022 Apr;28 Suppl 1(Suppl 1):940-2. doi: 10.1111/odi.13516.
18. Riad A, Pokorná A, Attia S, Klugarová J, Koščík M, Klugar M. Prevalence of COVID-19 Vaccine Side Effects among Healthcare Workers in the Czech Republic. *J Clin Med.* 2021 Apr;10(7):1428. doi: 10.3390/jcm10071428.



19. Sawires L. Effects of the influenza vaccine on the oral cavity [honors undergraduate theses]. Orlando: College of Health and Public Affairs; 2018.
20. Ramires MCCH, Mattia MB, Tateno RY, Palma LF, Campos L. A combination of phototherapy modalities for extensive lip lesions in a patient with SARS-CoV-2 infection. *Photodiagnosis Photodyn Ther.* 2021 Mar;33:102196. doi: 10.1016/j.pdpdt.2021.102196.