




Assessment of studies on oral manifestations and COVID-19: a meta-research study

Priscila Szymanski¹ , Rafael Sarkis-Onofre¹ , Bernardo Antonio Agostini¹ , Fernanda Ruffo Ortiz^{1,*} 

¹ Graduate Program in Dentistry, ATITUS Education, Passo Fundo, Brazil.

Corresponding author:

Fernanda Ruffo Ortiz
Graduate Program in Dentistry,
ATITUS Education,
304 Senador Pinheiro Street,
99070-220, Passo Fundo, Brazil.
Email: fernanda.ortiz@atitus.edu.br

Editor: Dr. Altair A. Del Bel Cury

Received: June 5, 2023

Accepted: October 25, 2023

Aim: This study aimed to evaluate how different study designs influences the presence and characteristics of diagnosis of oral manifestations in patients with COVID-19. **Methods:** This study is a meta-search conducted with studies evaluating the relationship between patients with oral manifestations and COVID-19. A search was conducted in three databases (PubMed, Web of Science, and Scopus), using terms specific to COVID-19 and oral lesions, including only primary studies. Study selection was undertaken by two reviewers independently. A descriptive analysis was performed. **Results:** The results included 55 studies in the data synthesis analysis. Most of the studies were case reports and case series. Some of the studies did not relate a biological test to confirm COVID-19. The ulcer lesion and that clinical examination by specialists were the most reported lesion in case reports and case series studies, while taste alterations and patient self-report were more reported in observational studies. **Conclusions:** This review concluded that the oral lesions in patients with COVID-19 differ according to the study design. The lack of high-quality scientific evidence in the dental literature on COVID-19 makes the findings inconsistent by the lack of sample selection criteria, diagnostic criteria and classification of oral lesions.

Keywords: Epidemiology. COVID-19. Methods. Diagnosis, oral.



Introduction

World Health Organization (WHO) declared a global pandemic for COVID-19 in early 2020. The rapid spread of the disease caused by the SARS-CoV-2 virus brought the need to produce quick answers on the topic, generating a substantial number of articles. In dentistry, it was no different. In the first year of the pandemic, more than one thousand five hundred articles were published in the PubMed database about "COVID-19 and Dentistry"¹. Despite the urgency of knowledge, this mass production also generated concern in the scientific community about the quality and accuracy of these studies².

The oral mucosa is one of the entry routes for SARS-CoV 2, arising from human salivary gland receptors, believing that oral symptoms such as loss of smell, taste, and xerostomia, may be precursor symptoms of COVID-19, even before the typical clinical symptoms³. Thus, the clinical picture pattern of this disease may include oral signs and symptoms⁴. A living systematic review, which aims to be updated every six months, reported in its first publication in 2020 that the most prevalent symptom was taste alteration⁵. In their last update, published in 2021, the authors analyzed an increase in the publication of studies on the topic and the most prevalent oral symptom, up to that point, was xerostomia, followed by taste alterations⁶. However, afterward, a cohort study of 154 patients positive for viral disease reported that the most prevalent oral manifestation was oral ulcers⁷, disagreeing with the results of previous systematic reviews^{5,6}.

Despite there are systematic reviews on this topic, most of the primary studies published diverge methodologically, assessed the prevalence of oral lesions as secondary outcomes⁸, presenting a lack of a plausible understanding of the establishment of the causal relationship between oral conditions and the virus⁶, and the diagnostic methods are not standardized which can jeopardize the understanding of this subject. Therefore, considering that previous literature presents different study designs involving COVID-19 and the oral manifestations with different results, this study aimed to evaluate how different study designs influences the presence and characteristics of diagnosis of oral manifestations in patients with COVID-19.

Methodology

This a meta-search study conducted with studies evaluating the relationship between patients with oral manifestations and COVID-19. The protocol for this study was previously registered with OSF Registries (<https://doi.org/10.17605/OSF.IO/MS2ZF>).

Eligibility criteria

We included studies published in scientific journals with adult subjects, with no maximum age restriction, who tested positive for COVID-19 through a confirmatory diagnostic test, which may be the results of the SARS-CoV-2 polymerase chain reaction (PCR) or other, and who reported some type of oral lesion, regardless of how this lesion was diagnosed. Original studies of any design such clinical trials, observational studies and case-reports were included. However, review articles, letters to

the editor, and pilot studies were excluded. Due to financial constraints, only studies in the English language were included. Review articles, letters to the editor, and pilot studies were excluded.

Search strategy

Searches were conducted in the electronic databases PubMed, Scopus, and Web of Science from January 1, 2020 (corresponding to the first reported cases of the disease worldwide) to November 1, 2022. The search strategy was designed for PubMed, based on Mesh terms and keywords, and after, adapted for the Scopus and Web of Science databases (full search strategies could be found in supplementary table 1). The references cited in the included articles were also reviewed to identify other relevant studies.

Selection process

After the search strategy, the studies were imported into the Rayyan QCRI program (<https://rayyan.qcri.org>) to perform duplicate article removal. A pilot test was conducted to test agreement in study selection between the reviewers involved in this phase. After, two reviewers independently reviewed the titles and abstracts of all studies. Articles meeting the eligibility criteria and those with insufficient data in the title and abstract were selected for full-text reading. Subsequently, the full-text reading was performed independently by the same two reviewers considering the same criteria once more. Discrepancies in selecting titles, abstracts, and full-text articles were resolved through discussion with a third reviewer until a consensus was reached.

Data extraction

For data collection, a standardized form was created using Excel software. Two reviewers analyzed the selected studies to test the data extraction and ensure consistency in the analysis and collection of information. Subsequently, one reviewer extracted the data from the included studies, and then the second reviewer checked the consistency of the data.

The following data were extracted: year of publication, first author name, the continent of study conduct, study design (randomized clinical trials, cross-sectional, cohort, case-control studies, case report or case series), diagnostic test for COVID-19 (PCR or other), presence and clinical presentation (signs and symptoms) of the oral lesion(s), time of manifestation of oral lesion symptomatology, and how the diagnosis of the oral lesion(s) was made (clinical examination, laboratory examination, teledentistry, or self-report). Case report was considered only when a single case was reported in the study, and case series were considered studies that reported two or more cases.

According to the eligibility criteria of this review, studies that had patients diagnosed with COVID-19 through a confirmatory test would be included. In contrast, some studies did not show this confirmation through a laboratory test, but rather the confirmation was through patient self-report. We chose not to exclude these studies

because we believe it would be important to discuss the lack of standardization in confirming the disease.

Data analysis

Data were analyzed using Stata 14.0 software. Descriptive analysis was performed to assess the relationship between the oral manifestations and COVID-19 in the different study designs. In addition, a comparison analysis was performed between the oral manifestations of the lesions that appeared most in the studies (ulcer, taste alteration, xerostomia, candidiasis, periodontal disease, and herpes simplex), diagnosis of oral manifestations (clinical examination, laboratory examination, or self-report/teleodontology), and the study design. Taste alteration was considered anosmia, dysgeusia, or ageusia. Periodontal disease was the report of gingival or periodontal disease. Results are presented as frequency (n) and percentage (%).

Results

Figure 1 shows a flow chart summarizing the article selection process. The search initially yielded 2064 potentially relevant articles (PubMed: n = 1151; Scopus: n = 559; Web of Science: n = 354), after removing duplicates, 1486 articles were included based on title and abstract, and among these, 95 articles were included for reading the full text. Finally, 55 studies were included in the data synthesis analysis.

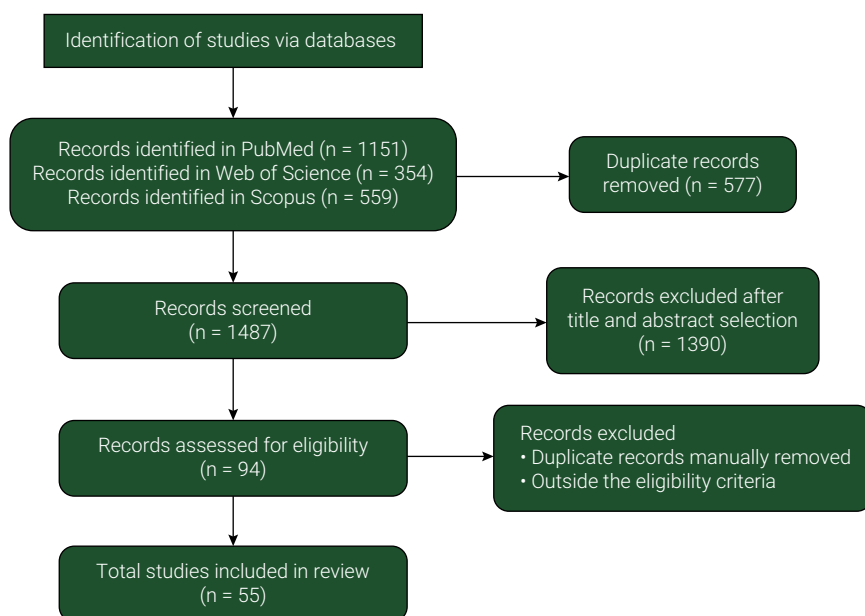


Figure 1. Flowchart of the selection process.

Supplementary Table 2 presents the list of included articles. The studies were conducted on four different continents, Asia (21 articles, 38.9%), America (14 articles, 25.9%), Europe (12 articles, 22.2%) and Africa (7 articles, 13.0%). Table 1 presents

the characteristics of included studies. Most of the studies were case reports (n=21, 38.2%) and case series (n=13, 23.6%), and among the analytical observational studies, 10 studies were cohort and cross-sectional studies (18.2%), and 1 study was case control (1.8%).

The PCR diagnostic test was the most used, present in 76.4% (n=42) of the articles. About half of the studies (43.6%, n=24), the oral manifestations were diagnosed by clinical examination (physician or dentist diagnosis). The oral manifestation most frequent was ulcer (60.0%, n=33), followed by taste alteration (n=22, 40.0%), and candidiasis described in 15 studies (27.3%) and xerostomia in 14 studies (25.5%). The described onset time of oral manifestations in the analyzed studies ranged from less than 21 days (before diagnosis of COVID-19) to 150 days after diagnosis of COVID-19.

Regarding the most prevalent lesion according to each type of study (Table 2), it was observed that ulcer lesion was the most reported in case report studies. In contrast, taste alteration was most present for analytical observational studies, followed by ulcer and xerostomia. When considering the type of examination, most studies that performed clinical and laboratory examinations were case reports and case series. Considering self-report and teledentistry, there was a slight preference for its use in analytical observational studies.

Table 1. Descriptive analysis of the analyzed articles (n=55).

Year of COVID-19 diagnosis	n (%)
2020	9 (16.4)
2021	25 (45.5)
2022	21 (38.1)
Study design	
Case report	21 (38.2)
Case series	13 (23.6)
Cross-sectional	10 (18.2)
Cohort	10 (18.2)
Caso-control	1 (1.8)
Diagnosis of Covid-19	
PCR*	42 (76.4)
Other	03 (5.4)
Not done/not available	10 (18.2)
Diagnosis of oral manifestations	
Clinical examination	24 (43.6)
Laboratory examination	13 (23.6)
Patient self-report or teledentistry	18 (32.8)
Ulcer	
No	22 (40.0)
Yes	33 (60.0)

Continue

Continuation	
Taste alteration**	
No	33 (60.0)
Yes	22 (40.0)
Candidiasis	
No	40 (72.7)
Yes	15 (27.3)
Xerostomia	
No	41 (74.5)
Yes	14 (25.5)
Periodontal diseases	
No	51 (92.7)
Yes	4 (7.3)
Herpes Simplex	
No	51 (92.7)
Yes	4 (7.3)

*PCR: polymerase chain reaction

**Taste alteration: anosmia, dysgeusia or ageusia

Supplementary table 1. Search strategy

PubMed

(("oral manifestations"[MeSH Terms] OR "oral manifestation" OR "oral lesion" OR "oral lesions" OR "oral mucosal lesion" OR "oral mucosal lesions" OR "mucocutaneous lesions" OR "oral alteration" OR "oral alterations" OR "pathology, oral"[MeSH Terms] OR "oral pathology" OR "oral pathologies" OR "oral complication" OR "oral complications" OR "oral change" OR "oral changes" OR "mouth diseases"[MeSH Terms] OR "mouth disease" OR "oral disease" OR "oral diseases") AND (("2019 nCoV" OR 2019nCoV OR "2019 novel coronavirus" OR "COVID 19" OR COVID19 OR "new coronavirus" OR "novel coronavirus" OR "SARSCoV-2" OR "COVID-19" OR "SARS-CoV" OR "2019-nCoV" OR "SARS-CoV-2" OR "coronavirus" OR coronavirus OR COVID OR SARS))

Scopus

(TITLE-ABS-KEY ("oral manifestations" OR "oral manifestation" OR "oral lesion" OR "oral lesions" OR "oral mucosal lesion" OR "oral mucosal lesions" OR "mucocutaneous lesions" OR "mucocutaneous viral lesions" OR "oral alteration" OR "oral alterations" OR "oral pathology" OR "oral pathologies" OR "oral complication" OR "oral complications" OR "oral change" OR "oral changes" OR "mouth diseases" OR "mouth disease" OR "oral disease" OR "oral diseases") AND TITLE-ABS-KEY ("2019 nCoV" OR 2019ncov OR "2019 novel coronavirus" OR "COVID 19 OR covid19 OR "new coronavirus" OR "novel coronavirus" OR "SARS CoV-2" OR covid-19 OR sars-cov OR 2019-ncov OR sars-cov 2 OR coronavirus OR covid OR sars))

Web of Science

TS= (oral manifestations OR oral manifestation OR oral lesion OR oral lesions OR oral mucosal lesion OR oral mucosal lesions OR mucocutaneous lesions OR mucocutaneous viral lesions OR oral alteration OR oral alterations OR oral pathology OR oral pathologies OR oral complication OR oral complications OR oral change OR oral changes OR mouth diseases OR mouth disease OR oral disease OR oral diseases) AND TS=(2019 nCoV OR 2019ncov OR 2019 novel coronavirus OR COVID 19 OR covid19 OR new coronavirus OR novel coronavirus OR SARS CoV-2 OR covid-19 OR sars-cov OR 2019-ncov OR coronavirus OR covid OR sars OR sars-cov-2)

Table 2. Comparison analysis between the oral manifestations of lesions, their diagnoses, and the design of the studies (n=55).

	Case report	Case series	Cross-sectional	Cohort	Caso-Control
Ulcer					
No	9 (40.9)	4 (18.2)	3 (13.6)	5 (22.7)	1 (4.6)
Yes	12 (36.4)	9 (27.3)	7 (21.2)	5 (15.1)	0 (0.0)
Taste alteration*					
No	17 (51.5)	8 (24.2)	3 (9.1)	4 (12.1)	1 (3.1)
Yes	4 (18.2)	5 (22.7)	7 (31.8)	6 (27.3)	0 (0.0)
Candidiasis					
No	18 (45.0)	8 (20.0)	8 (20.0)	5 (12.5)	1 (2.5)
Yes	3 (20.0)	5 (33.3)	2 (13.4)	5 (33.3)	0 (0.0)
Xerostomia					
No	20 (48.8)	11 (26.8)	5 (12.2)	4 (9.8)	1 (2.4)
Yes	1 (7.1)	2 (14.3)	5 (35.7)	6 (42.9)	0 (0.0)
Periodontal disease					
No	21 (41.2)	13 (25.5)	9 (17.6)	8 (15.7)	0 (0.0)
Yes	0 (0.0)	0 (0.0)	1 (25.0)	2 (50.0)	1 (25.0)
Herpes simplex					
No	20 (39.3)	12 (23.6)	9 (17.6)	9 (17.6)	1 (1.9)
Yes	1 (25.0)	1 (25.0)	1 (25.0)	1 (25.0)	0 (0.0)
Diagnosis of oral manifestations					
Clinical examination	11 (45.8)	5 (20.8)	3 (12.5)	4 (16.7)	1 (4.2)
Laboratory examination	6 (46.1)	5 (38.5)	0 (0.0)	2 (15.4)	0 (0.0)
Patient self-report or teledentistry	4 (22.2)	3 (16.7)	7 (38.9)	4 (22.2)	0 (0.0)

*Taste alteration: anosmia, dysgeusia or ageusia.

Supplementary table 2. Data extraction.

Year	Author	Continent	Design of study	Oral manifestation	Diagnosis of COVID-19	Diagnosis of oral lesion
2020	Amorim dos Santos et al. ⁹	American	Case report	Ulcer e Taste alteration	PCR	Clinical examination.
2020	Brandão et al. ¹⁰	American	Case series	Ulcer, Taste alteration, herpes	PCR	Laboratory examination.
2020	Corchuelo et al. ¹¹	American	Case report	Candidiasis, ulcer	PCR	Teledentistry and self-report.
2020	Cruz Tapia et al. ¹²	American	Case series	Taste alteration, ulcer	PCR	Laboratory and clinical examination.
2020	Fantozzi et al. ¹³	Europe	Cohort	Taste alteration, xerostomia	PCR	Self-report.
2020	Sinjari et al. ¹⁴	Europe	Cohort	Taste alteration, xerostomia	N/A	Self-report.
2020	Zarch et al. ¹⁵	Asian	Case report	Xerostomia, taste alteration, ulcer	PCR	Teledentistry.
2020	Biadsee et al. ¹⁶	Asian	Case series	Xerostomia, Taste alteration	PCR	Self-report.
2020	Kitakawa et al. ¹⁷	American	Case report	Ulcer	PCR	Clinical examination.
2021	Subramaniam et al. ¹⁸	Asian	Case series	Ulcer, candidiasis, Taste alteration	PCR	Clinical examination.
2021	Gherlone et al. ¹⁹	Europe	Cohort	Xerostomia, taste alteration	PCR	Clinical examination.
2021	Abdelgabar et al. ²⁰	Europe	Case report	Ulcer	PCR	Laboratory examination.
2021	Fisher et al. ²¹	American	Case report	Edema	N/A	Laboratory examination.
2021	Favia et al. ²²	Europe	Cross-sectional	Ulcer	PCR	Laboratory examination.
2021	Saleh et al. ²³	African	Case report	Oral lichen planus	N/A	Laboratory and clinical examination.
2021	Naser et al. ²⁴	Asian	Cohort	Ulcer, necrosis, taste alteration, parotiditis	PCR	Clinical examination.
2021	Nejabi et al. ²⁵	Asian	Case report	Ulcer	PCR	Clinical examination.
2021	El Kady et al. ²⁶	African	Cohort	Taste alteration, xerostomia, candidiasis, Ulcer	PCR	Self-report.
2021	Carreras-Presas et al. ²⁷	Europe	Case series	Ulcer	N/A	Teledentistry.
2021	Eita et al. ²⁸	African	Case report	Taste alteration	PCR	Clinical examination.
2021	Katz ²⁹	American	Cross-sectional	Candidiasis	PCR	Self-report.
2021	Elamrousy et al. ³⁰	African	Cross-sectional	Taste alteration, xerostomia, candidiasis, ulcer	PCR	Clinical examination, Self-report.

Continue

Continuation

2021	Abubakr et al. ³¹	African	Cross-sectional	Halitose, ulcerações, xerostomia	PCR	Self-report.
2021	Natto et al. ³²	Asian	Cross-sectional	Taste alteration, periodontal desisases, ulcer	PCR	Self-report and clinical examination.
2021	Hocková et al. ³³	Europe	Case series	Ulcer, parotiditis	PCR	Clinical examination.
2021	Saleh et al. ³⁴	African	Case report	Ulcer, herpes zoster	N/A	Clinical examination.
2021	Teixeira et al. ³⁵	American	Case series	Ulcer, candidiasis	PCR	Clinical examination.
2021	Dalipi et al. ³⁶	Europe	Case report	Ulcer	PCR	Clinical examination.
2021	Fathi et al. ³⁷	Asian	Case report	Ulcer	PCR	Clinical examination.
2021	Ramires et al. ³⁸	American	Case report	Ulcer	PCR	Clinical examination.
2021	Nuño González et al. ³⁹	Europe	Cross-sectional	Edema, ulcer, mucositis	PCR	Clinical examination.
2021	Rai et al. ⁴⁰	Asian	Case series	Candidiasis, ulcer	PCR	Clinical examination.
2021	Jawanda et al. ⁴¹	Asian	Case report	Mucormycose, Actinomicose, Candidiasis, Osteomyelitis	PCR	Laboratory examination.
2021	Khodavirdipour et al. ⁴²	Asian	Case series	Xerostomia, ulcer, Taste alteration	PCR	Clinical examination and self-report.
2022	Anand et al. ⁴³	Asian	Caso-control	Periodontal desisases	PCR	Clinical examination.
2022	Aswin et al. ⁴⁴	Asian	Case report	Mucormycose	N/A	Laboratory examination.
2022	Ganesan et al. ⁴⁵	Asian	Cross-sectional	Taste alteration, xerostomia, candidiasis, ulcer	PCR	Clinical examination.
2022	Yeom et al. ⁴⁶	American	Case series	Ulcer, candidiasis	N/A	Laboratory examination.
2022	Walsh et al. ⁴⁷	American	Cohort	Edema	N/A	Clinical examination.
2022	Palaia et al. ⁴⁸	Europe	Case report	Ulcer	PCR	Clinical examination.
2022	Koračin et al. ⁴⁹	Europe	Case report	Cheilitis	PCR	Laboratory examination.
2022	Hans et al. ⁵⁰	Asian	Cross-sectional	Taste alteration, ulcer	PCR	Teledentistry and self-report.
2022	Schwab et al. ⁷	American	Cohort	Candidiasis, herpes	PCR	Laboratory and clinical examination.
2022	Reis et al. ⁵¹	American	Cross-sectional	Taste alteration	PCR	Self-report.

Continue

Continuation

2022	Poorna et al. ⁵²	Asian	Case report	Ludwig' Angina	Other	Laboratory examination.
2022	Talahatu et al. ⁵³	Asian	Case report	Ulcer	N/A	Teledentistry.
2022	Dilsiz et al. ⁵⁴	Asian	Case report	Ulcer	PCR	Clinical examination.
2022	Eduardo et al. ⁵⁵	American	Cohort	Xerostomia, candidiasis	PCR	Clinical examination.
2022	Muthyam et al. ⁵⁶	Asian	Cross-sectional	Xerostomia, ulcer, Taste alteration	PCR	Self-report.
2022	Chawla et al. ⁵⁷	Asian	Cross-sectional	Xerostomia, Taste alteration, ulcer	PCR	Clinical examination and self-report.
2022	Al-Mahalawy et al. ⁵⁸	African	Case series	Osteonecrosis	PCR	Laboratory examination
2022	Tantawi et al. ⁵⁹	African	Cross-sectional	Xerostomia, Taste alteration	PCR	Self-report.
2022	Al-Ak'hali et al. ⁶⁰	Asian	Case report	Ulcer	PCR	Laboratory examination.
2022	Gebretsadik et al. ⁶¹	African	Cohort	Ulcer, xerostomia, candidiasis	N/A	Clinical examination.
2022	Binmadi et al. ⁶²	Asian	Cohort	Taste alteration, xerostomia, candidiasis, Ulcer	Self-report	Teledentistry and self-report.

PCR: polymerase chain reaction

N/A: not available

Discussion

This was the first article to verify the influence of study design in the report of oral manifestations of COVID-19 related articles. We found that the reported oral manifestations are different depending on the study design, as well as there is a divergence and non-standardization of the diagnostic method performed in these studies. Moreover, there is no standardization in reporting the data evaluated, such as oral lesions.

Related to the oral lesions identified, ulcer was the most reported lesion in case reports and case series studies, agreeing with previous literature^{22,63}. Furthermore, these studies presented a diagnosis of the oral manifestations through clinical examination. A possible explanation for this finding is that these lesions were more noticeable due to the direct damage to the oral tissue and mucosa, causing pain and discomfort, often requiring specialized care by patients⁸. In addition, some publications show that the edema⁴⁷ and ulcers were found in patients who required oxygen or intubation⁷ and it is unlikely that these oral lesions were a direct manifestation of the virus or a marker of the progression of COVID-19⁷. In this sense, the relationship between ulcers and COVID-19 should be interpreted with caution, as they may be biased by the study design and lack of theoretical causal plausibility.

In agreement with previous literature, the oral condition that appeared the most in the group of analytical observational studies was taste alteration^{13,14,26,51}, diagnosed by questionnaires and patient self-report^{5,64,65}. There is still no consensus on

the hypothesis and mechanism of action between COVID-19 and taste alteration; however, the data collection method of these studies can be discussed. Applying data collection by questionnaires and online format may make it easier to interpret oral symptoms, such as loss of taste, and have hindered the visual diagnosis of other oral lesions, thus making it challenging to interpret oral signs and symptoms during or after COVID-19⁶⁵. Moreover, one of the first reports of symptomatology in COVID-19 patients was taste alteration. This report may have had a placebo effect on patients, being a consequence of previous reports from other patients about such a symptomatologic possibility and may have then caused interference when answering the questionnaire⁶⁶.

After analyzing the studies in this research, some oral lesions were reported in a smaller number, such as herpes simplex^{10,67}, oral lichen planus⁶⁸, mucormycosis^{41,44}, and osteonecrosis⁵⁸, among others⁴³. These manifestations may be considered opportunistic lesions with great potential to affect patients, often resulting from actions for the treatment of COVID-19 and the deterioration of systemic health⁹. Other authors also report that several factors can affect the oral mucosa and trigger numerous lesions, including lack of oral hygiene during the disease, stress, and secondary infections⁶⁸. In addition, these manifestations are some of the most common factors which can cause immune dysregulation in the oral cavity⁶⁸ and be present in patients with COVID-19.

Most of the studies analyzed were case reports and case series, which critically agree with other reviews that mapped the level of evidence of published studies on COVID-19⁸. These studies have the lowest level of scientific evidence when considering the different pyramids of evidence⁶⁹ because they have several methodological biases, no comparison group, and low reproducibility. The fact that no clinical trials were found shows the scarcity of studies with high methodological levels within the theme and when discussing the level of evidence. However, because this is a pandemic period, with restrictive measures and no knowledge about the disease scenario, the large number of case report studies and case series becomes plausible. Moreover, cohort studies are a reliable design to determine the occurrence of the disease, identify risk factors, and even determine a causal relationship. In the present review, these studies were most of the analytical observational studies found. Being aware that the hierarchical scale of evidence is not linear⁷⁰ and when well conducted, a cohort study can be very reliable⁷¹.

An important aspect to consider in this study is that most of the studies performed the diagnosis of lesions through clinical examination by health professionals, but the use of criteria for diagnosis of lesions or training and calibration of examiners was not reported. The diagnosis of oral diseases has a high degree of subjectivity and depends of professional qualification, so the World Health Organization (WHO) recommends and reports that it is crucial to use the technical guide to calibrate oral disease examiners⁷². Furthermore, taking into consideration that the diagnostic method performed was basically visual/tactile in clinical examinations, the possibility of reproducibility and sensitivity become weak, and some diseases may also not be recognized by examiners, causing a lack of diagnoses or underestimated lesions in each population⁷³.

With the impact of the pandemic, a minimal understanding of the behavior of the virus was necessary and, in the face of the restrictive measures imposed to contain the advance of the disease, one of the ways to produce and conduct new research was through teledentistry and online surveys with self-report^{74,75}. In the group of analytical observational studies that were analyzed, self-report and teledentistry were methods commonly used as diagnosis. However, according to previous literature, online surveys do not guarantee consistent validity of results because there are limitations such as sample characterization and data collection method used, which may influence the research results⁷⁴. In this sense, different results between analytical observational studies and case reports/series may be related to the conduct of the study design, sample selection bias, and the use of non-validated methods, which may cause response bias or affect specific groups of people assessed⁷⁵.

There are some limitations of this study that need to be emphasized. First, COVID-19 is still a new disease, and its manifestations, characteristics, and sequelae are still challenging for researchers. Next, the lack of standardization in the questionnaires used, and the classification and nature of the lesions may have reflected on the results of this research since it made it difficult to collect the data in a standardized manner. Moreover, the necessity of rapid responses about covid and its consequences to reduce its harms and damages may be contributed for the researchers neglect some methodological aspects or reduce its quality criteria. However, the revisors of this study were trained to avoid errors or lack of data from the studies found. Third, the language restriction for selecting articles was only in English, which may have provided the non-inclusion of studies written in other languages since the pandemic started in China. However, English is considered the universal language in science, and studies conducted in Asia were found in greater numbers in this review.

Future research on this topic is encouraged to better plan the design of their studies, including designed studies with careful sample selection, training, and calibration for data collection for the examination of oral manifestations, and standardizing the diagnostic methods of the evaluated diseases.

This study concluded that the oral lesions present in patients with COVID-19 are different according to the study design and that these differences may be related to the diagnostic method used and the way of data reporting.

Acknowledgements

FRO and RSO are funded in part by Meridional Foundation (Passo Fundo – Brazil). This study was conducted in a Graduate Program supported by CAPES, Brazil – Finance Code 001.

Conflicts of interest

The authors declare that they have no conflicts of interest.

Author contribution

Priscila Szymanski: Investigation, Formal analysis, Writing - original draft.

Rafael Sarkis-Onofre: Methodology, Writing – review & editing.

Bernardo Antonio Agostini: Methodology, Writing - review & editing.

Fernanda Ruffo Ortiz: Conceptualization, Methodology, Supervision, Writing - review & editing.

All authors actively participated in the manuscript's findings and have revised and approved the final version of the manuscript.

References

1. Pubmed. National Library of Medicine. "COVID-19 and Dentistry". 2020 [cited 2023 Mar 2]. Available from: <https://pubmed.ncbi.nlm.nih.gov/?term=covid-19+and+dentistry&filter=years.2020-2020>.
2. Jacimovic J, Jakovljevic A, Nagendrababu V, Duncan HF, Dummer PMH. A bibliometric analysis of the dental scientific literature on COVID-19. *Clin Oral Investig*. 2021 Nov;25(11):6171-83. doi: 10.1007/s00784-021-03916-6.
3. Freni F, Meduri A, Gazia F, Nicastro V, Galletti C, Aragona P, et al. Symptomatology in head and neck district in coronavirus disease (COVID-19): a possible neuroinvasive action of SARS-CoV-2. *Am J Otolaryngol*. 2020 Sep-Oct;41(5):102612. doi: 10.1016/j.amjoto.2020.102612.
4. Erbaş GS, Botsali A, Erden N, Arı C, Taşkın B, Alper S, et al. COVID-19-related oral mucosa lesions among confirmed SARS-CoV-2 patients: a systematic review. *Int J Dermatol*. 2022 Jan;61(1):20-32. doi: 10.1111/ijd.15889.
5. Amorim Dos Santos J, Normando AGC, Carvalho da Silva RL, Acevedo AC, De Luca Canto G, Sugaya N, et al. Oral manifestations in patients with COVID-19: a 6-month update. *J Dent Res*. 2021 Nov;100(12):1321-9. doi: 10.1177/00220345211029637.
6. Amorim Dos Santos J, Normando AGC, Carvalho da Silva RL, Acevedo AC, De Luca Canto G, Sugaya N, et al. Oral manifestations in patients with COVID-19: a living systematic review. *J Dent Res*. 2021;100(2):141-54. doi: 10.1177/0022034520957289.
7. Schwab G, Palmieri M, Zerbini RM, Sarmento DJS, Reis T, Ortega KL, et al. Lack of direct association between oral mucosal lesions and SARS-CoV-2 in a cohort of patients hospitalised with COVID-19. *J Oral Microbiol*. 2022 Mar;14(1):2047491. doi: 10.1080/20002297.2022.2047491.
8. Sharma P, Malik S, Wadhwan V, Gotur Palakshappa S, Singh R. Prevalence of oral manifestations in COVID-19: a systematic review. *Rev Med Virol*. 2022 Nov;32(6):e2345. doi: 10.1002/rmv.2345.
9. Amorim Dos Santos J, Normando AGC, Carvalho da Silva RL, De Paula RM, Cembranel AC, Santos-Silva AR, et al. Oral mucosal lesions in a COVID-19 patient: New signs or secondary manifestations? *Int J Infect Dis*. 2020;97:326-8. doi: 10.1016/j.ijid.2020.06.012.
10. Brandão TB, Gueiros LA, Melo TS, Prado-Ribeiro AC, Nesrallah ACFA, Prado GVB, et al. Oral lesions in patients with SARS-CoV-2 infection: could the oral cavity be a target organ? *Oral Surg Oral Med Oral Pathol Oral Radiol*. 2021 Feb;131(2):e45-e51. doi: 10.1016/j.oooo.2020.07.014. Epub 2020 Aug 18.
11. Corchuelo J, Ulloa FC. (2020). Oral manifestations in a patient with a history of asymptomatic COVID-19: case report. *Int J Infect Dis*. 2020 Nov;100:154-7. doi: 10.1016/j.ijid.2020.08.071.
12. Cruz Tapia RO, Peraza Labrador AJ, Guimaraes DM, Matos Valdez LH. Oral mucosal lesions in patients with SARS-CoV-2 infection. Report of four cases. Are they a true sign of COVID-19 disease? *Spec Care Dentist*. 2020 Nov;40(6):555-60. doi: 10.1111/scd.12520.

13. Fantozzi PJ, Pampena E, Di Vanna D, Pellegrino E, Corbi D, Mammucari S, et al. Xerostomia, gustatory and olfactory dysfunctions in patients with COVID-19. *Am J Otolaryngol*. 2020 Nov-Dec;41(6):102721. doi: 10.1016/j.amjoto.2020.102721.
14. Sinjari B, D'Ardes D, Santilli M, Rexhepi I, D'Addazio G, Di Carlo P, et al. SARS-CoV-2 and Oral Manifestation: An Observational, Human Study. *J Clin Med*. 2020 Oct;9(10):3218. doi: 10.3390/jcm9103218.
15. Zarch RE, Hosseinzadeh P. COVID-19 from the perspective of dentists: A case report and brief review of more than 170 cases. *Dermatol Ther*. 2021 Jan;34(1):e14717. doi: 10.1111/dth.14717.
16. Biadsee A, Biadsee A, Kassem F, Dagan O, Masarwa S, Ormianer Z. Olfactory and oral manifestations of COVID-19: sex-related symptoms-a potential pathway to early diagnosis. *Otolaryngol Head Neck Surg*. 2020 Oct;163(4):722-8. doi: 10.1177/0194599820934380.
17. Kitakawa D, Oliveira FE, Neves de Castro P, Carvalho LFCS. Short report - Herpes simplex lesion in the lip semimucosa in a COVID-19 patient. *Eur Rev Med Pharmacol Sci*. 2020 Sep;24(17):9151-3. doi: 10.26355/eurrev_202009_22863.
18. Subramaniam T, Nikalje MR, Jadhav S. Oral manifestations among COVID-19: An observational study of 713 patients. *Dent Res J (Isfahan)*. 2021 Aug 18;18:67.
19. Gherlone EF, Polizzi E, Tetè G, De Lorenzo R, Magnaghi C, Rovere Querini P, et al. Frequent and persistent salivary gland ectasia and oral disease After COVID-19. *J Dent Res*. 2021 May;100(5):464-71. doi: 10.1177/0022034521997112.
20. Abdelgabar A, Elsayed M. Case of erythema multiforme/Stevens-Johnson syndrome: an unusual presentation of COVID-19. *J R Coll Physicians Edinb*. 2021 Jun;51(2):160-61. doi: 10.4997/JRCPE.2021.214.
21. Fisher J, Monette DL, Patel KR, Kelley BP, Kennedy M. COVID-19 associated parotitis. *Am J Emerg Med*. 2021 Jan;39:254.e1-254.e3. doi: 10.1016/j.ajem.2020.06.059.
22. Favia G, Tempesta A, Barile G, Brienza N, Capodiferro S, Vestito MC, et al. Covid-19 Symptomatic patients with oral lesions: clinical and histopathological study on 123 cases of the University Hospital Policlinic of Bari with a purpose of a new classification. *J Clin Med*. 2021 Feb;10(4):757. doi: 10.3390/jcm10040757.
23. Saleh W, Ata F, Elashry MM. Is COVID-19 infection triggering oral herpes zoster? A case report. *SAGE Open Med Case Rep*. 2021 Dec 16;9:2050313X211065793. doi: 10.1177/2050313X211065793.
24. Naser AI, Al-Sarraj MN, Deleme ZH. Oral and maxillofacial lesions in COVID 19 infection from mosul hospital in iraq: epidemiological study and approach to classification and treatment. *J Oral Res*. 2021;10(6):1-14. doi: 10.17126/joralres.2021.069.
25. Nejabi MB, Noor NAS, Raufi N, Essar MY, Ehsan E, Shah J, et al. Tongue ulcer in a patient with COVID-19: a case presentation. *BMC Oral Health*. 2021 May;21(1):273. doi: 10.1186/s12903-021-01635-8.
26. El Kady DM, Gomaa EA, Abdella WS, Ashraf Hussien R, Abd ElAziz RH, Khater AGA. Oral manifestations of COVID-19 patients: an online survey of the Egyptian population. *Clin Exp Dent Res*. 2021 Oct;7(5):852-60. doi: 10.1002/cre2.429.
27. Carreras-Presas MC, Amaro Sánchez J, López-Sánchez AF, Jané-Salas E, Somacarrera Pérez ML. Oral vesiculobullous lesions associated with SARS-CoV-2 infection. *Oral Dis*. 2021 Apr;27 Suppl 3(Suppl 3):710-2. doi: 10.1111/odi.13382.
28. Eita AAB. Parosmia, Dysgeusia, and Tongue Features Changes in a Patient with Post-Acute COVID-19 Syndrome. *Case Rep Dent*. 2021 Aug;2021:3788727. doi: 10.1155/2021/3788727.
29. Katz J. Prevalence of candidiasis and oral candidiasis in COVID-19 patients: a cross-sectional pilot study from the patients' registry in a large health center. *Quintessence Int*. 2021 Jul;52(8):714-18. doi: 10.3290/j.qi.b1491959.

30. Elamrousy WAH, Nassar M, Issa DR. Prevalence of oral lesions in COVID-19 Egyptian patients. *J Int Soc Prev Community Dent*. 2021 Nov;11(6):712-20. doi: 10.4103/jispcd.JISPCD_221_21.
31. Abubakr N, Salem ZA, Kamel AHM. Oral manifestations in mild-to-moderate cases of COVID-19 viral infection in the adult population. *Dent Med Probl*. 2021 Jan-Mar;58(1):7-15. doi: 10.17219/dmp/130814.
32. Natto ZS, Afeef M, Khalil D, Kutubaldin D, Dehathem M, Alzahrani A, et al. Characteristics of oral manifestations in symptomatic non-hospitalized COVID-19 patients: a cross-sectional study on a sample of the Saudi population. *Int J Gen Med*. 2021 Dec;14:9547-53. doi: 10.2147/IJGM.S331611.
33. Hocková B, Riad A, Valky J, Šulajová Z, Stebel A, Slávik R, et al. Oral complications of ICU patients with COVID-19: case-series and review of two hundred ten cases. *J Clin Med*. 2021 Feb;10(4):581. doi: 10.3390/jcm10040581.
34. Saleh W, Ata F, Elashry MM. Is COVID-19 infection triggering oral herpes zoster? A case report. *SAGE Open Med Case Rep*. 2021 Dec 16;9:2050313X211065793. doi: 10.1177/2050313X211065793.
35. Teixeira IS, Leal FS, Tateno RY, Palma LF, Campos L. Photobiomodulation therapy and antimicrobial photodynamic therapy for orofacial lesions in patients with COVID-19: A case series. *Photodiagnosis Photodyn Ther*. 2021 Jun;34:102281. doi: 10.1016/j.pdpdt.2021.102281.
36. Dalipi ZS, Dragidella F, Dragidella DK. Oral manifestations of exudative erythema multiforme in a patient with COVID-19. *Case Rep Dent*. 2021 Aug;2021:1148945. doi: 10.1155/2021/1148945.
37. Fathi Y, Hoseini EG, Mottaghi R. Erythema multiform-like lesions in a patient infected with SARS-CoV-2: a case report. *Future Virol*. 2021 Feb;10.2217/fvl-2020-0333. doi: 10.2217/fvl-2020-0333.
38. Ramires MCCH, Mattia MB, Tateno RY, Palma LF, Campos L. A combination of phototherapy modalities for extensive lip lesions in a patient with SARS-CoV-2 infection. *Photodiagnosis Photodyn Ther*. 2021 Mar;33:102196. doi: 10.1016/j.pdpdt.2021.102196.
39. Nuño González A, Magaletskyy K, Martín Carrillo P, Lozano Masdemont B, Mayor Iburguren A, Feito Rodríguez M, et al. Are oral mucosal changes a sign of COVID-19? a cross-sectional study at a field hospital. *Actas Dermosifiliogr (Engl Ed)*. 2021 Feb;112(7):640-4. doi: 10.1016/j.ad.2021.02.007.
40. Rai A, Kumar A, Rana A, Singh S, Sybil D. Oral findings in patients with COVID-19 infection: report of two cases and review of literature. *J Pharmac Res Int*. 2021;33(47B):265-73. doi: 10.9734/jpr/2021/v33i47B33123.
41. Jawanda MK, Narula R, Gupta S, Sharma V, Sidhu SK, Kaur N. Mixed infections (Mucormycosis, Actinomycosis and Candidiasis) leading to maxillary osteomyelitis in a diabetic mellitus patient in post COVID phase: first case report. *Acta Medica (Hradec Kralove)*. 2021;64(4):218-23. doi: 10.14712/18059694.2022.5.
42. Khodavirdipour A, Asadimanesh M, Masoumi SA. Impact of SARS-CoV-2 genetic blueprints on the oral manifestation of COVID-19: a case report. *Glob Med Genet*. 2021 Sep;8(4):183-5. doi: 10.1055/s-0041-1735538.
43. Anand PS, Jadhav P, Kamath KP, Kumar SR, Vijayalaxmi S, Anil S. A case-control study on the association between periodontitis and coronavirus disease (COVID-19). *J Periodontol*. 2022 Apr;93(4):584-90. doi: 10.1002/JPER.21-0272.
44. Aswin AI, Gunasekaran S, Thankappan P, Joseph TI. An atypical case report of extensive mucormycotic osteomyelitis of maxilla as a consequence of post-COVID complication. *Dent Res J (Isfahan)*. 2022 Jul 18;19:60.
45. Ganesan A, Kumar S, Kaur A, Chaudhry K, Kumar P, Dutt N, et al. Oral manifestations of COVID-19 infection: an analytical cross-sectional study. *J Maxillofac Oral Surg*. 2022 Dec;21(4):1326-35. doi: 10.1007/s12663-021-01679-x.

46. Yeom J, Wolk R, Griffin L, Freedman PD, Reich RF. Atypical herpetic ulcerations in COVID-19 positive patients: A report of three cases. *Oral Surg Oral Med Oral Pathol Oral Radiol.* 2023 Feb;135(2):268-71. doi: 10.1016/j.oooo.2022.07.015. Epub 2022 Jul 29.
47. Walsh A, Peesay T, Newark A, Shearer S, Parsa K, Pierce M, et al. Association of severe tongue edema with prone positioning in patients intubated for COVID-19. *Laryngoscope.* 2022 Feb;132(2):287-9. doi: 10.1002/lary.29773.
48. Palaia G, Pernice E, Pergolini D, Impellizzeri A, Migliau G, Gambarini G, et al. Erythema multiforme as early manifestation of COVID-19: a case report. *Pathogens.* 2022 Jun;11(6):654. doi: 10.3390/pathogens11060654.
49. Koračin V, Balkovec V, Jurčić V. Granulomatous cheilitis in a patient after SARS-CoV-2 infection treated with antibiotics: a case report. *Acta Dermatovenol Alp Pannonica Adriat.* 2022 Mar;31(Suppl):S36-8. doi: 10.15570/actaapa.2022.s12.
50. Hans M, Hans VM, Kahlon N, Sagar M, Pandey AK, Das A. Gustatory dysfunction and oral ulceration in COVID-19 patients: a cross sectional study. *Dent Res J (Isfahan).* 2022 Jun;19:43. doi: 10.4103/1735-3327.346401.
51. Reis D, Sartoretto SC, Calasans-Maia MD, Louro RS, Moraschini V. Long-term prevalence of taste and olfactory dysfunction in COVID-19 patients: a cross-sectional study. *Oral Dis.* 2022 Nov;28 Suppl 2:2516-2521. doi: 10.1111/odi.14231.
52. Poorna TA, Lokesh JR, Joshna Ek, John B. Ludwig's angina in a COVID positive patient-An atypical case report. *Spec Care Dentist.* 2022 Jan;42(1):99-102. doi: 10.1111/scd.12643.
53. Talahatu LB, Kaban BE, Ayuningtyas NF, Brilyanti IN, Parmadiati AE, Radithia D, et al. Management of patients with aphthous-like ulcers related to aplastic anaemia in the COVID-19 pandemic era through teledentistry: a case report. *Majalah Kedokteran Gigi.* 2022 Mar;55(1):49-55. doi: 10.20473/j.djmk.v55.i1.p49-55.
54. Dilsiz A, Parlak E, Gül SS. Oral and ocular manifestations in a patient with coronavirus disease-2019: clinical presentation and management. *Rev Soc Bras Med Trop.* 2022 Apr;55:e06992021. doi: 10.1590/0037-8682-0699-2021.
55. Eduardo FP, Bezinelli LM, Gobbi MF, Bergamin LG, de Carvalho DLC, Corrêa L. Oral lesions and saliva alterations of COVID-19 patients in an intensive care unit: A retrospective study. *Spec Care Dentist.* 2022 Sep;42(5):494-502. doi: 10.1111/scd.12705.
56. Muthyam AK, Reddy MP, Kulkarni S, Srilatha A, Sahithi K, Satyanarayana D. Oral manifestations in COVID-19 patients: An observational study. *J Family Med Prim Care.* 2022 Mar;11(3):1000-5. doi: 10.4103/jfmpc.jfmpc_1264_21.
57. Chawla J, Navaneeth Y, Bakshi SS, Kalidoss VK, Yadav S, Polineni S, et al. Oral manifestations associated with COVID-19 disease: An observational cross sectional study. *J Oral Biol Craniofac Res.* 2022 Mar-Apr;12(2):279-83. doi: 10.1016/j.jobcr.2022.03.008.
58. Al-Mahalawy H, El-Mahallawy Y, Dessoky NY, Ibrahim S, Amer H, Ayad HM, et al. Post-COVID-19 related osteonecrosis of the jaw (PC-RONJ): an alarming morbidity in COVID-19 surviving patients. *BMC Infect Dis.* 2022 Jun;22(1):544. doi: 10.1186/s12879-022-07518-9.
59. Tantawi ME, Sabbagh HJ, Alkhateeb NA, Quritum M, Abourdan J, Qureshi N, et al. Oral manifestations in young adults infected with COVID-19 and impact of smoking: a multi-country cross-sectional study. *PeerJ.* 2022 Jul;10:e13555. doi: 10.7717/peerj.13555.
60. Al-Ak'hali MS, Halboub E, Ibraheem W, Khan HK, Hummadi AM. Recurring oral erythema multiforme-like lesions elicited by COVID-19 infection: a case report. *Braz Dent Sci.* 2022;25(1):1-7. doi: 10.4322/bds.2022.e2960.

61. Gebretsadik HG. An update on oral clinical courses among patients with severe acute respiratory syndrome coronavirus 2 (SARS-CoV-2) infection: A clinical follow-up (a prospective prevalent cohort) study. *PLoS One*. 2022 Oct;17(10):e0275817. doi: 10.1371/journal.pone.0275817.
62. Binmadi NO, Aljohani S, Alsharif MT, Almazrooa SA, Sindi AM. oral manifestations of COVID-19: a cross-sectional study of their prevalence and association with disease severity. *J Clin Med*. 2022 Jul ;11(15):4461. doi: 10.3390/jcm11154461.
63. Aragoneses J, Suárez A, Algar J, Rodríguez C, López-Valverde N, Aragoneses JM. Oral manifestations of COVID-19: updated systematic review with meta-analysis. *Front Med (Lausanne)*. 2021 Aug;8:726753. doi: 10.3389/fmed.2021.726753.
64. Klein H, Asseo K, Karni N, Benjamini Y, Nir-Paz R, Muszkat M, et al. Onset, duration and unresolved symptoms, including smell and taste changes, in mild COVID-19 infection: a cohort study in Israeli patients. *Clin Microbiol Infect*. 2021 Feb;27(5):769-74. doi: 10.1016/j.cmi.2021.02.008.
65. Vinayachandran D, Balasubramanian S. Is gustatory impairment the first report of an oral manifestation in COVID-19? *Oral Dis*. 2021 Apr;27 Suppl 3(Suppl 3):748-9. doi: 10.1111/odi.13371.
66. Daniali H, Flaten MA. Experiencing COVID-19 symptoms without the disease: the role of placebo in reporting of symptoms. *Scand J Public Health*. 2022 Feb;50(1):61-9. doi: 10.1177/14034948211018385.
67. Elamrousy WAH, Nassar M, Issa DR. Prevalence of oral lesions in COVID-19 Egyptian patients. *J Int Soc Prev Community Dent*. 2021 Nov;11(6):712-20. doi: 10.4103/jispcd.JISPCD_221_21.
68. Saleh W, SHawky E, Halim GA, Ata F. Oral lichen planus after COVID-19, a case report. *Ann Med Surg (Lond)*. 2021 Dec;72:103051. doi: 10.1016/j.amsu.2021.103051.
69. Murad MH, Asi N, Alsawas M, Alahdab F. New evidence pyramid. *Evid Based Med*. 2016 Aug;21(4):125-7. doi: 10.1136/ebmed-2016-110401.
70. Marques DM, Kuchenbecker RS. Considerations on the use of scientific evidences in times of a pandemic: the case of COVID-19. *Vigil Sanit Debate*. 2020;8(2):2-9. doi: 10.22239/2317-269X.01541.
71. Villarosa AR, Ramjan LM, Maneze D, George A. Conducting population health research during the covid-19 pandemic: Impacts and recommendations. *Sustainability*. 2021;13(6):1-11. doi: 10.3390/su13063320.
72. Kramer IR, Pindborg JJ, Bezroukov V, Infirri JS. Guide to epidemiology and diagnosis of oral mucosal diseases and conditions. World Health Organization. *Community Dent Oral Epidemiol*. 1980 Feb;8(1):1-26. doi: 10.1111/j.1600-0528.1980.tb01249.x.
73. da Silva KD, da Rosa WLO, Sarkis-Onofre R, Aitken-Saavedra JP, Demarco FF, Correa MB, et al. Prevalence of oral mucosal lesions in population-based studies: a systematic review of the methodological aspects. *Community Dent Oral Epidemiol*. 2019 Oct;47(5):431-40. doi: 10.1111/cdoe.12477.
74. Boni RB. Web surveys in the time of COVID-19. *Cad Saude Publica*. 2020;36(7):e00155820. doi: 10.1590/0102-311x00155820.
75. De Man J, Campbell L, Tabana H, Wouters E. The pandemic of online research in times of COVID-19. *BMJ Open*. 2021 Feb;11(2):e043866. doi: 10.1136/bmjopen-2020-043866.